MARIA
MIDDELARES
GezondheidsZorg met een Ziel

ROTATORCUFF TEARS

A standardized approach

dr. Pieter-Bastiaan De Keyzer

MARIA MIDDELARES

GezondheidsZorg met een Ziel

THE BASICS

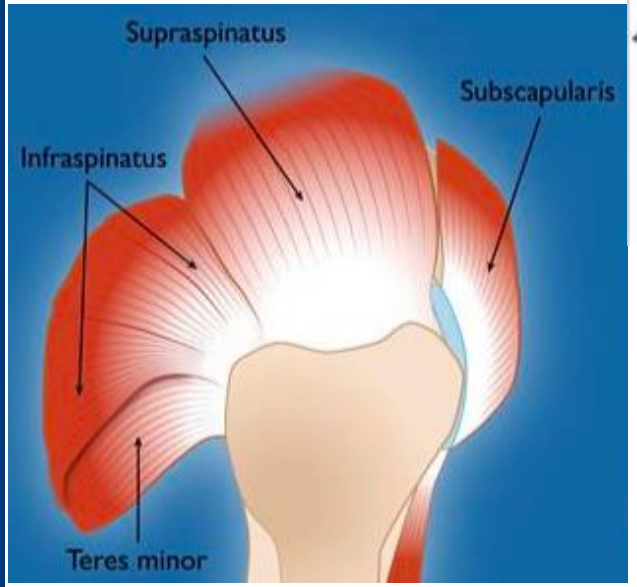

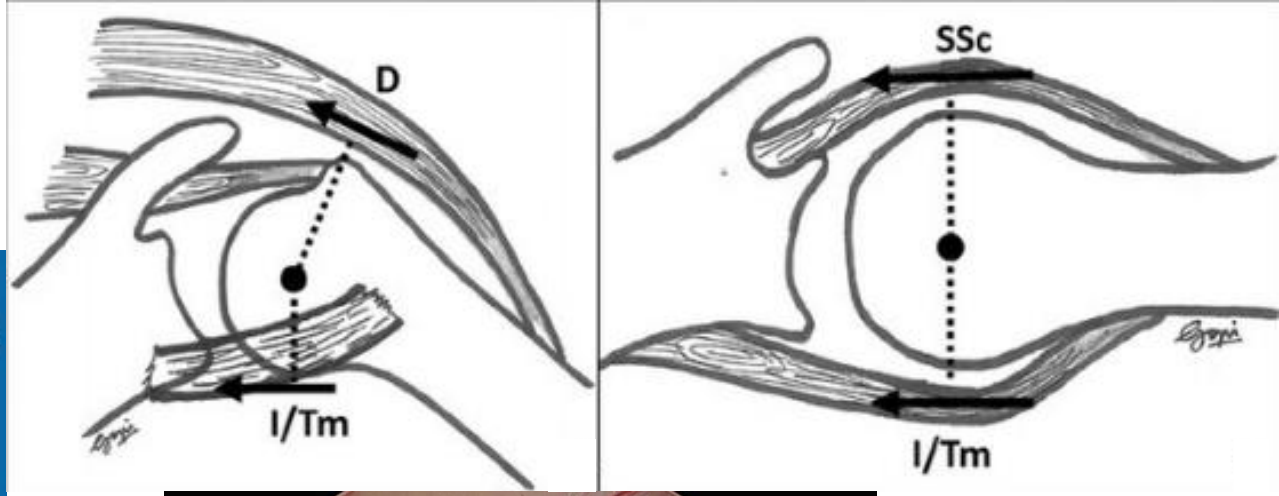

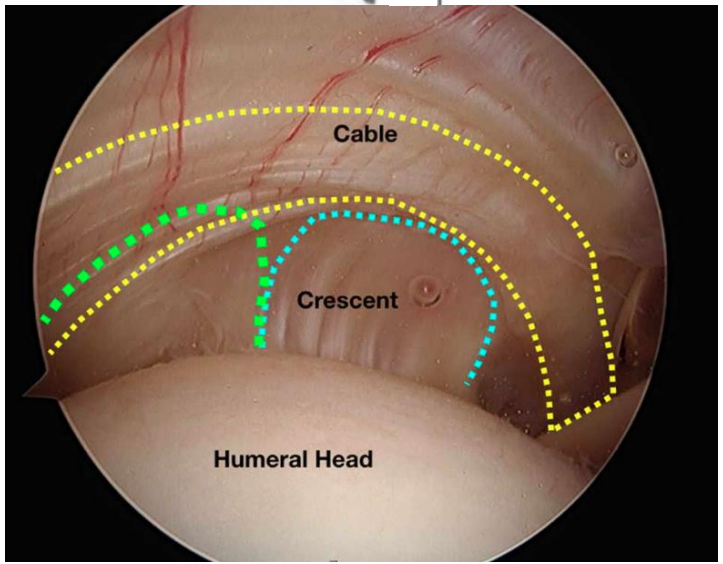

MARIA MIDDELARES

TEARS

Ethiology:

Traumatic

Degenerative

(Overuse)

Type:

Complete

Partial

- Articular
- Bursal
- (Intrasubstance)

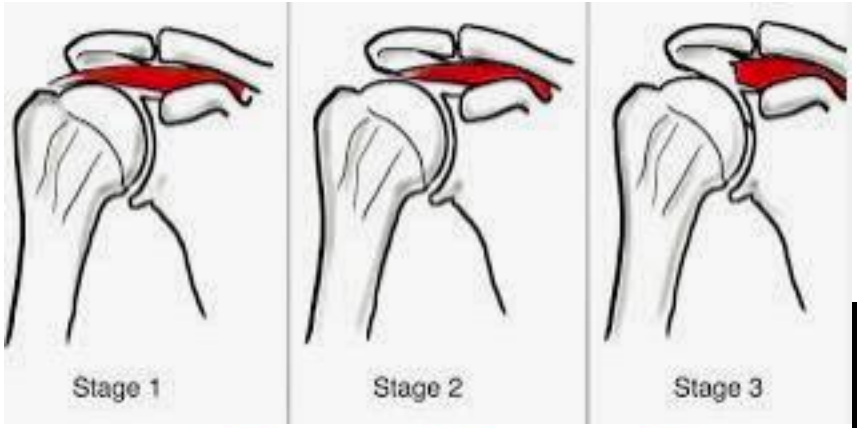

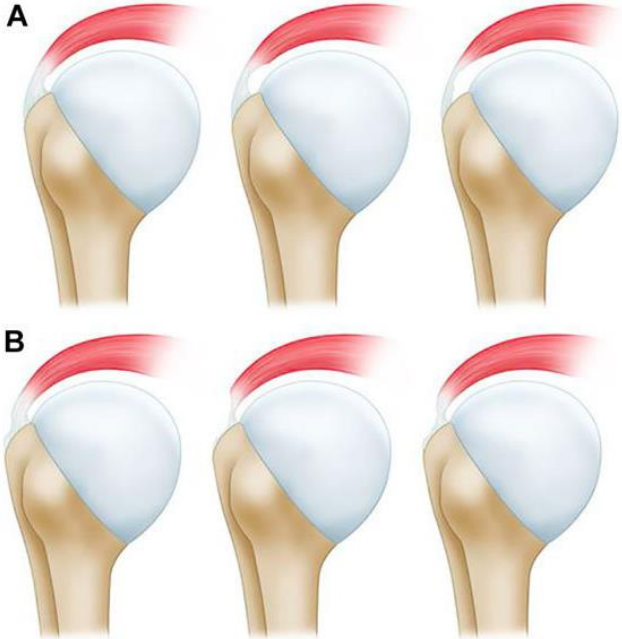

MARIA MIDDELARES

ANAMNESIS

- Age – sex – work – sports/hobbies
- Risk factors:
  - Smoking
  - Diabetes
  - Alcohol
  - Depression
- Injured side/Dominant side
- Trauma mechanism
- Stiffness
- Pain
  - Location
  - Irradiation
  - Night
  - Click
- Strength

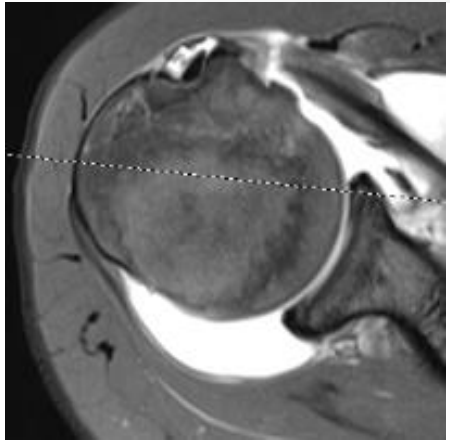

MARIA MIDDELARES

PHYSICAL EXAM

- ROM: Active / Passive
- Impingement
  - Hawkins
  - Yochum
- Cuff
  - Ssp: Jobe (empty can)
  - Isp/TM: ER1 - ER2
  - Ssc: Gerber / Belly Press / Bear Hug
  - Lag Signs: ER/Hornblower / Lift off
- Biceps
  - Speed / O’brien
- AC
- Instability



MARIA MIDDELARES

DIAGNOSTICS

Ultrasound

Pro:
- Non-invasive
- Cheap
- Readily available
- Accurate
    - Sens: 84 – 96%
    - Spec: 89 - 93%
- Dynamic (Biceps)
- +/- infiltration

Con:
- Operator dependent

Xray

Views:
- Grashey (AP Oblique)
- ER
- Outlet / Y-view
- Axillary

Assessment:
- Critical Shoulder Angle (*)
- Acromiohumeral distance (1)
- Arthrosis
- Ca^{2+}
- Fracture (Trauma)
- AC

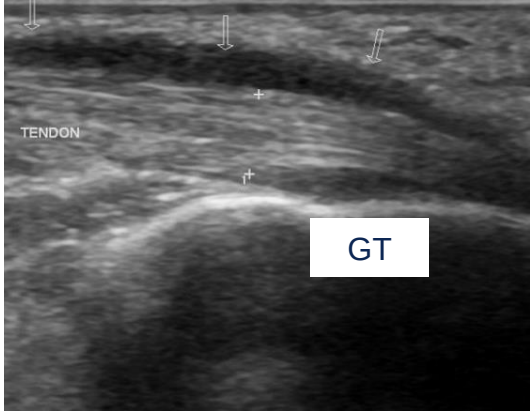

MARIA MIDDELARES

DIAGNOSTICS

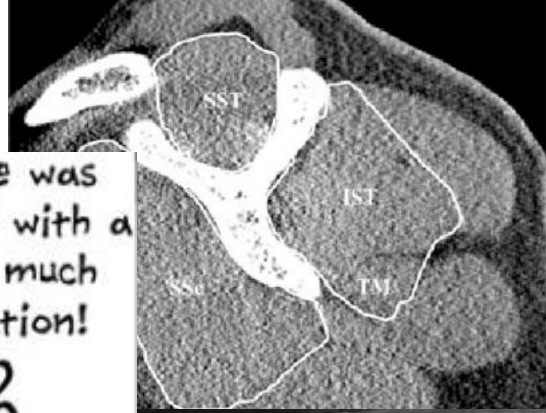

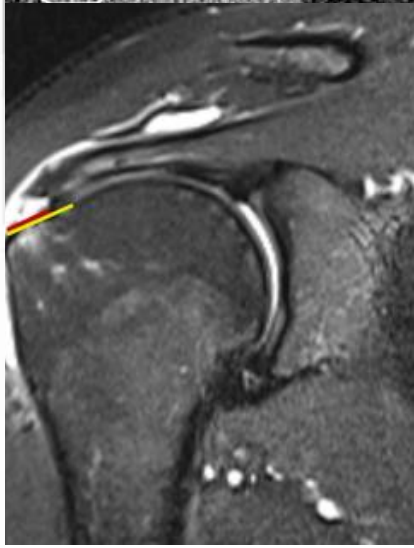

MARIA MIDDELARES

TREATMENT

Conservative (6w – 3m Degenerative/Partial tears)

NSAID

Physiotherapy:

- Posterior capsular stretching
- Scapular settings
- Tonifications remaining cuff (Isp/Tm/Ssc) + Deltoid
- Absence pain/slight discomfort
- Home excercises

Corticosteroid injection:

- Pain at night – Degenerative tear
- 1x - effect +/-3 months
- No influence retear rate
- Blind vs. ultrasound? 13-71% missed

PRP?

ESWT?

IN ORDER TO SUCCEED, WE MUST FIRST BELIEVE THAT WE CAN.

MARIA MIDDELARES

SURGERY

WHO?

Age <70

<50 fatty infiltration

No signs cuff arthropathy (AHD>6mm)

NO capsulitis

Failed conservative treatment

- Degenerative full thickness tears
- Partial tears: Debridement < 50% < Repair

Traumatic Tears

Late repair (>2y) → ↑ Retear rate (Tan et al. 2016)

Early repair (<4 months) → Functional outcomes (Gutman et al 2021)

MARIA MIDDELARES

SURGERY FULL THICKNESS TEARS

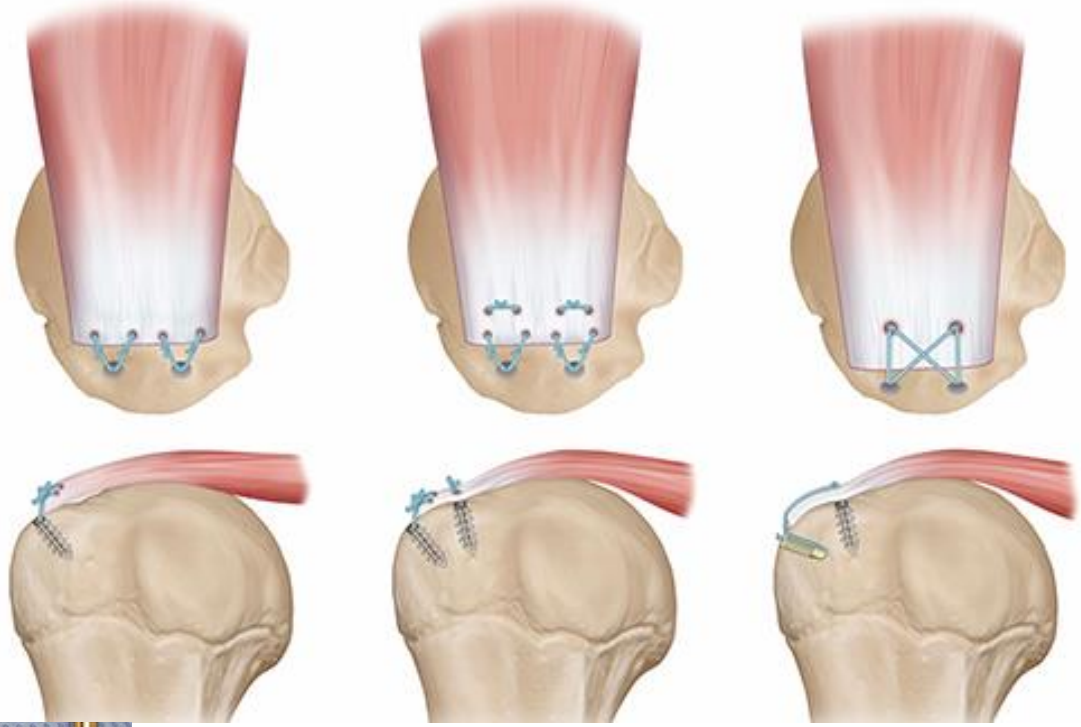

MARIA MIDDELARES

SURGERY PARTIAL THICKNESS TEARS

PASTA

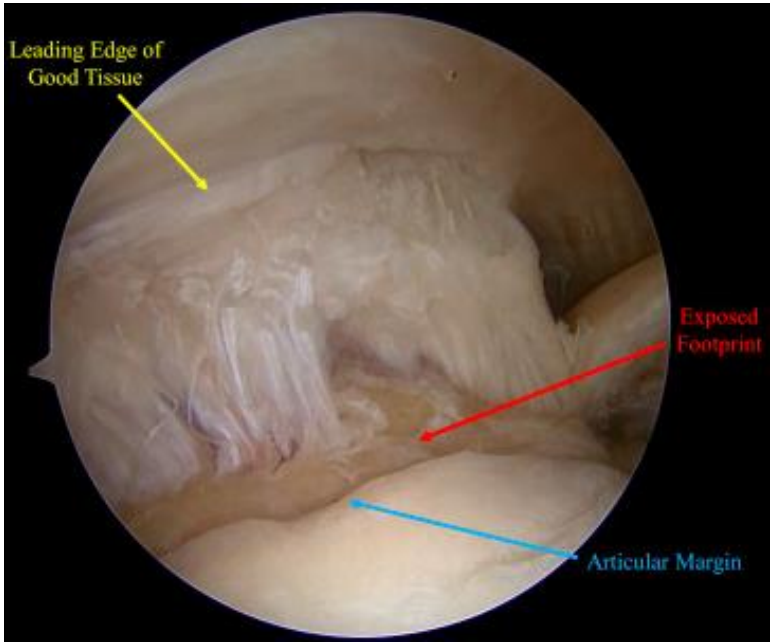

Bursal Side

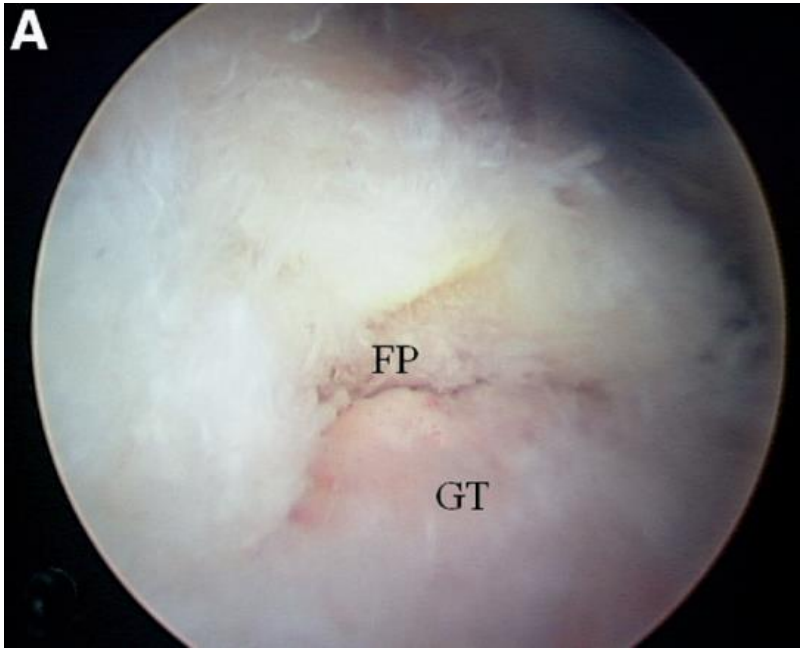

MARIA MIDDELARES

SURGERY PARTIAL THICKNESS TEARS

MARIA MIDDELARES

OUTCOMES

Open vs. Arthroscopic

= VAS

= Function

Arthroscopy → ↑ Surgery time

Open → ↑ Adverse events
↑ Hospital stay
↑ Readmission

Degenerative tears

Survivorship 5y= 94%, 10y= 83% (Millet et al.2011)

Clinical improvement: 6 months (Hughes et al. 2012)

Return to work: 8,1m +/- 2,7m (Cole et al. 2021)

Return to sports: 78% (Klouche et al. 2016)

Tendon healing: +/-90% (SFA 2013)

≈ Conservative treatment

Traumatic Tears

Late repair (>2y) → ↑ Retear rate (Tan et al. 2016)

<4 months → Functional outcomes(Gutman et al 2021)

MARIA MIDDELARES

IRREPARABLE?

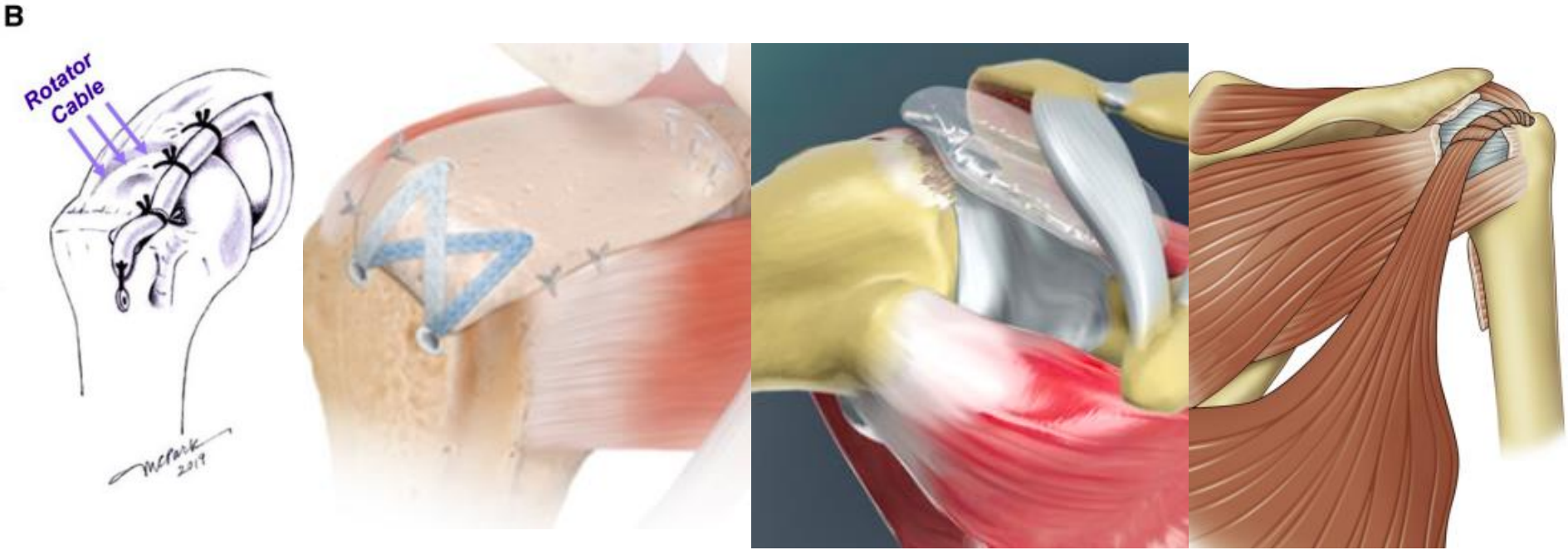

MARIA MIDDELARES

ALGORYTHM

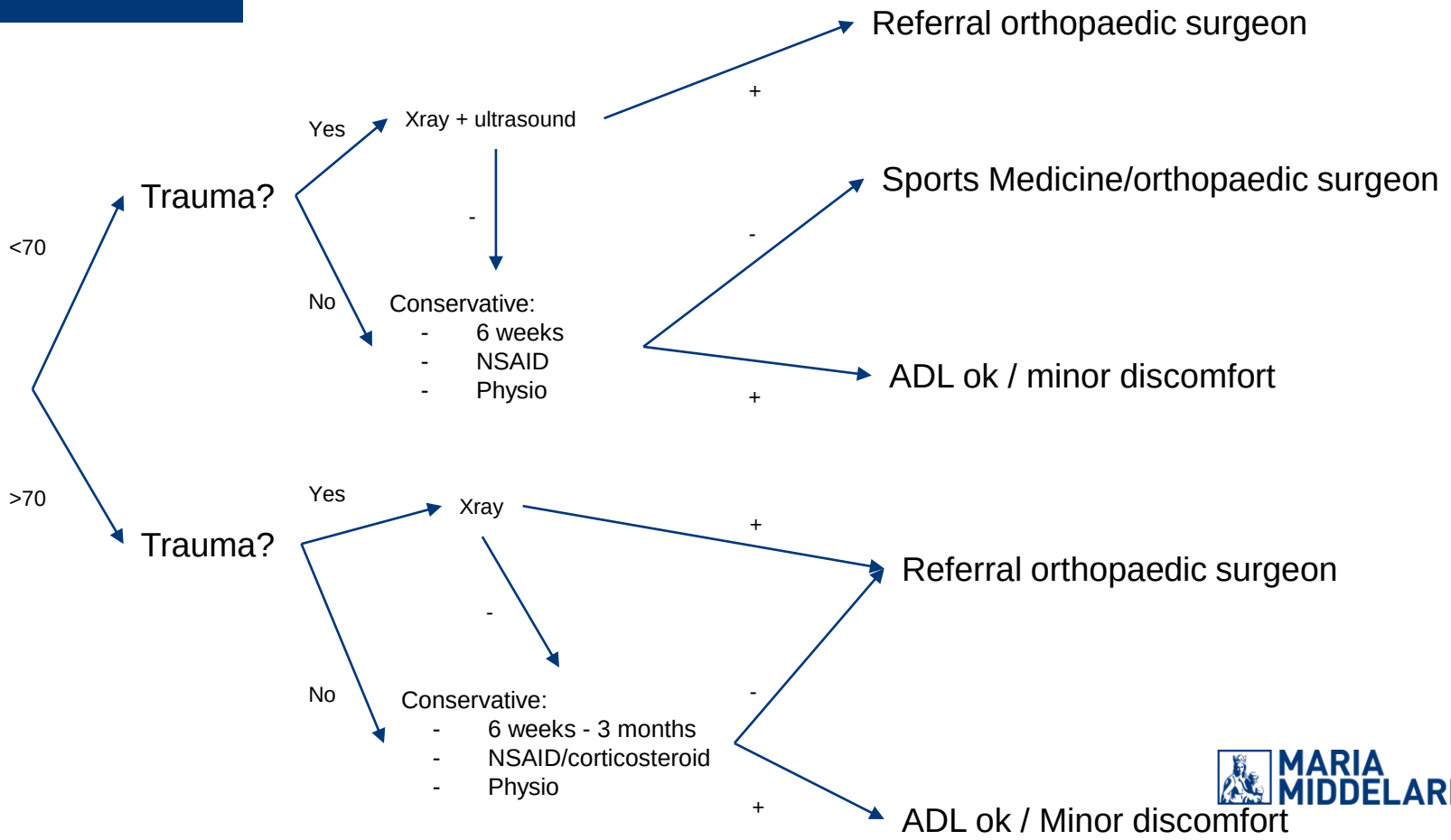

MARIA MIDDELARES

CONCLUSION

- Degenerative tears = conservative
- Traumatic tears: Act swift!
- Respect biology
- Xray + Ultrasound → Diagnosis
- CTa, MRa = pré-operative assessment
- The exception proves the rule!

MARIA MIDDELARES

dr. Pieter-Bastiaan De Keyzer
PieterBastiaan.DeKeyzer@azmmsj.be

MARIA MIDDELARES

GezondheidsZorg met een Ziel

Lid van E17 ziekenhuis netwerk