Musculoskeletale indicaties

Rol van SPECT/CT

Dr. Jeroen Mertens

Medische kring 29/01/2019

MARIA MIDDELARES

GezondheidsZorg met een Ziel

NUCLEAIRE GENEESKUNDE
AZ Maria Middelares
Buitenring Sint-Denijs 30
9000 Gent
Tel.: 09 246 96 00

MARIA MIDDELARES

Dr. Frank Temmerman
Dr. Bieke Van Den Bossche
Prof. Dr. Bieke Lambert
Dr. Jeroen Mertens

Identificatie van de patiënt Kamer:
Naam: ..... Voornaam: .....
geb. datum: .....

kleefvignet

datum, ster

Kopie naar:

Vink aan indien van toepassing:

☐Zwangerschap / Borstvoeding ☐ Besmettingsgevaar:
☐ Isolatie patiënt ☐ Andere opmerking:
☐ Allergie:

Vorige relevar

☐CT:
☐MRI:
☐Echo:
☐Andere:

Diagnostische vraagstelling:

Relevante klinische inlichtingen:

AANVRAAG VOOR ISOTOPENONDERZOEK
voorgesteld onderzoek:

AANVRAAG VOOR SPECT-CT
voorgesteld onderzoek / richtlijnen

SKELET
☐ Skeletscintigrafie
☐ Vasculaire scan
☐ WBC - Granulocyten

ENDOCRINOLOGIE
☐ Schildklier
☐ Bijschildklier
☐ Bijnier (merg/cortex)

HERSENEN
☐ Perfusie NeuroSPECT
☐ DAT-scan
☐ PET (cfr aparte aanvraag)

VARIA
☐ Gastric banding
☐ Lymfescan BL/OL
☐ Speekselklierscan
☐ Inflammatie/infectie
☐ Andere:

ONCOLOGIE
☐ Sentinelklier
☐ Porth-a-cath
☐ MIBG
☐ I123-scan totaal lichaam
☐ PET-scan (cfr aparte aanvraag)
☐ Andere:

NIEREN
☐ Morfologie / splitfunctie (DMSA)
☐ Renogram (+ Lasix)
☐ Captopril test
☐ GFR met Cr51-EDTA

MAAG-DARM-LEVER
☐ Maagevacuatie (nuchter!)
☐ GO reflux (nuchter!)
☐ Leverfunctie / galwegen (HIDA)
☐ Opsporen Meckel / GI-bloeding
☐ Andere:

NUCLEAIR
☐ I-131 hypert
☐ I-131 schildk
☐ Xofigo (Ra-2
☐ Quadramet (
☐ SIRT lever (
☐ Radiosynove
☐ Andere:

HART - LO
☐ Ventrikelfun
☐ LV (plana
☐ RV+LV ((
☐ Myocardperf
☐ Stress °fietsproef
°Persantine (LBBB!)
☐ Rust
☐ Rechts-links shunt
☐ V/Q scan
☐ % verdeling

AANVRAAG VOOR ISOTOPENONDERZOEK
voorgesteld onderzoek:

SKELET
☐ Skeletscintigrafie
☐ Vasculaire scan
☐ WBC - Granulocyten

ENDOCRINOLOGIE
☐ Schildklier
☐ Bijschildklier
☐ Bijnier (merg/cortex)

HERSENEN
☐ Perfusie NeuroSPECT
☐ DAT-scan
☐ PET (cfr aparte aanvraag)

VARIA
☐ Gastric banding
☐ Lymfescan BL/OL
☐ Speekselklierscan
☐ Inflammatie/infectie
☐ Andere:

ONCOLOGIE
☐ Sentinelklier
☐ Porth-a-cath
☐ MIBG
☐ I123-scan totaal lichaam
☐ PET-scan (cfr aparte aanvraag)
☐ Andere:

NIEREN
☐ Morfologie / splitfunctie (DMSA)
☐ Renogram (+ Lasix)
☐ Captopril test
☐ GFR met Cr51-EDTA

MAAG-DARM-LEVER
☐ Maagevacuatie (nuchter!)
☐ GO reflux (nuchter!)
☐ Leverfunctie / galwegen (HIDA)
☐ Opsporen Meckel / GI-bloeding
☐ Andere:

NUCLEAIRE THERAPIE
☐ I-131 hyperthyroïdie
☐ I-131 schildkliercarcinoom
☐ Xofigo (Ra-223)
☐ Quadramet (Sm-153)
☐ SIRT lever (Y90-sfeertjes)
☐ Radiosynovectomie
☐ Andere:

HART - LONGEN
☐ Ventrikelfunctie (EF)
☐ LV (planair / MIBI)
☐ RV+LV (GBS)
☐ Myocardperfusie (MIBI) (nuchter!)
☐ Stress °fietsproef
°Persantine (LBBB!)
☐ Rust
☐ Rechts-links shunt
☐ V/Q scan
☐ % verdeling

MARIA MIDDELARES

MARIA MIDDELARES

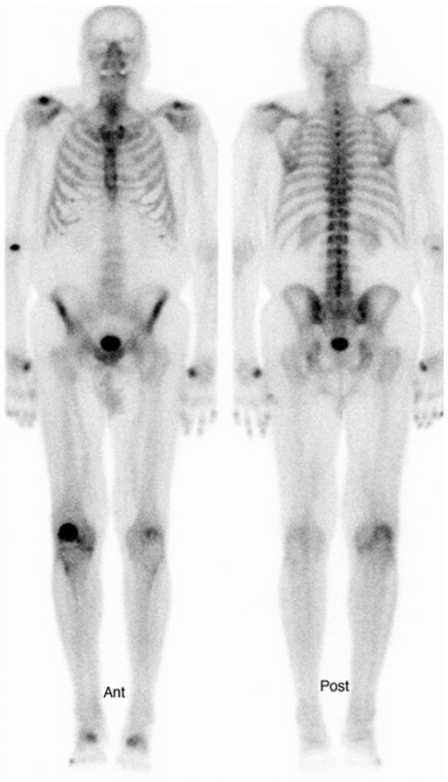

Poly-artrose

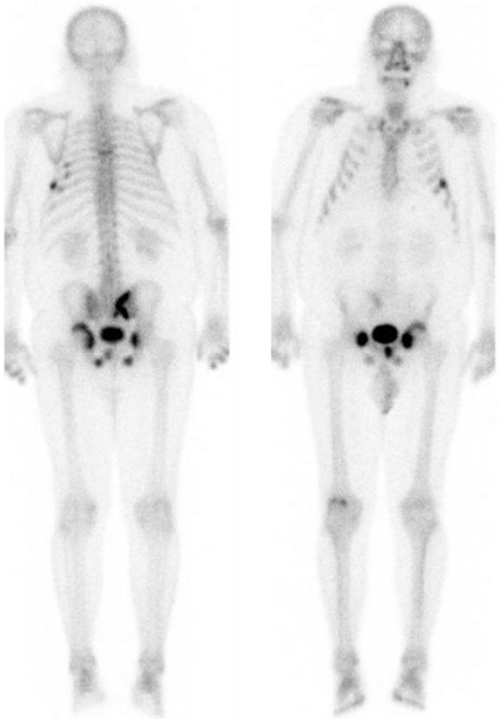

Fractuurhaarden

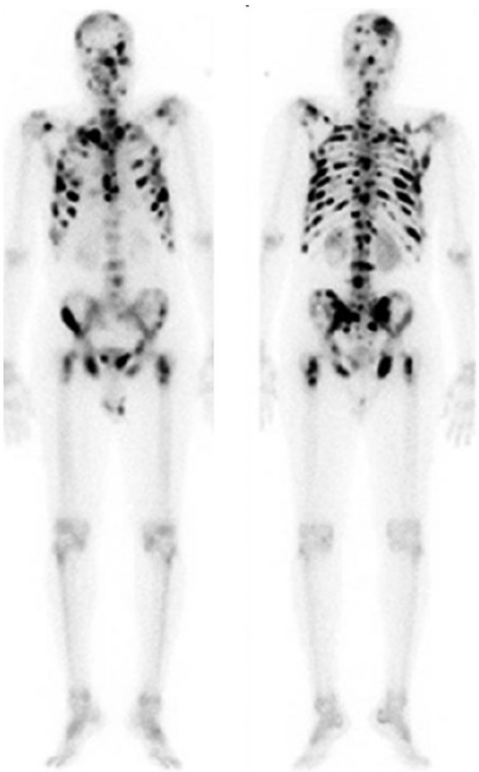

Metastasering

MARIA MIDDELARES

CRPS / Sudeck dystrofie

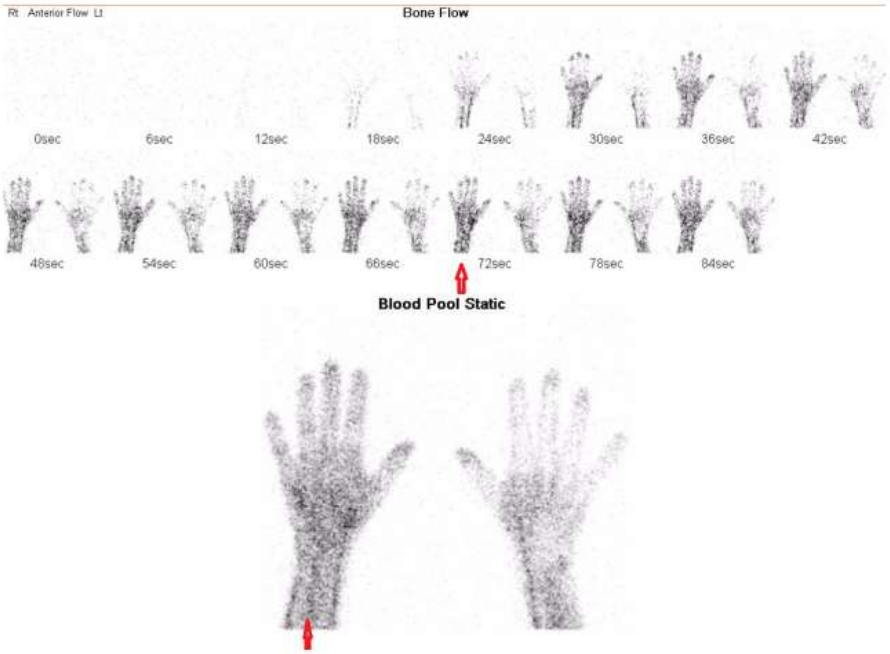

MARIA MIDDELARES

Arthritis

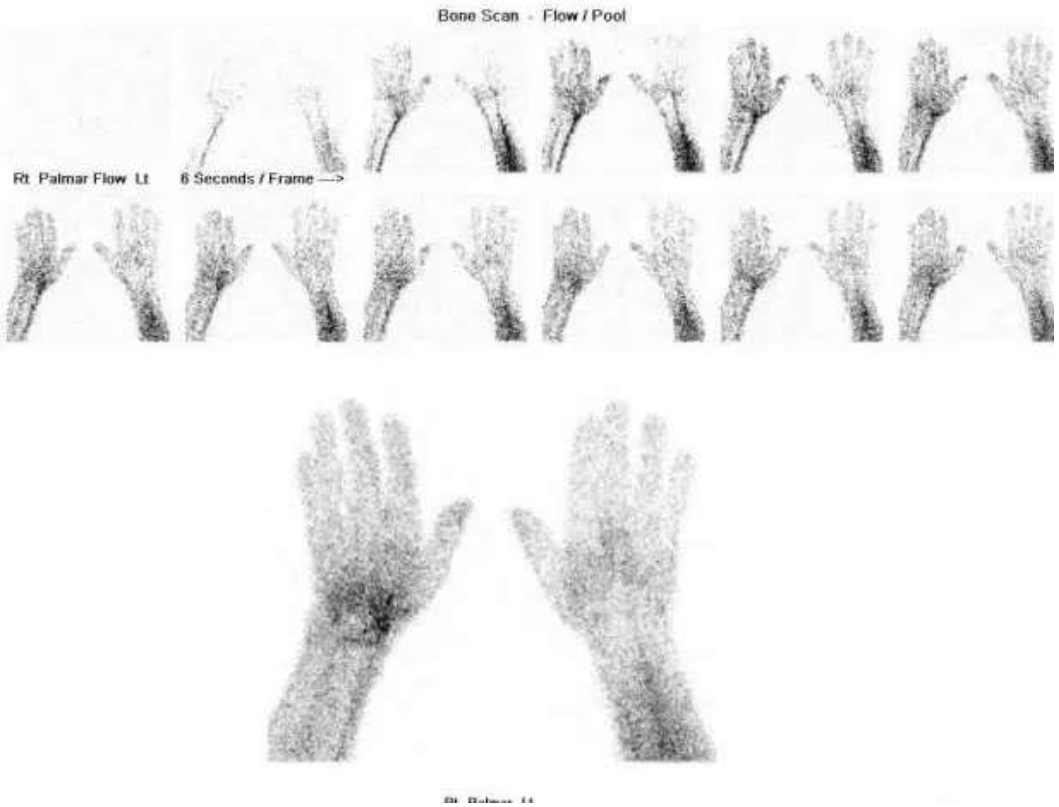

MARIA MIDDELARES

♂, 22j., pijn achtervoet, recidiverende enkeldistorsies



MARIA MIDDELARES

Talocalcaneale coalitie

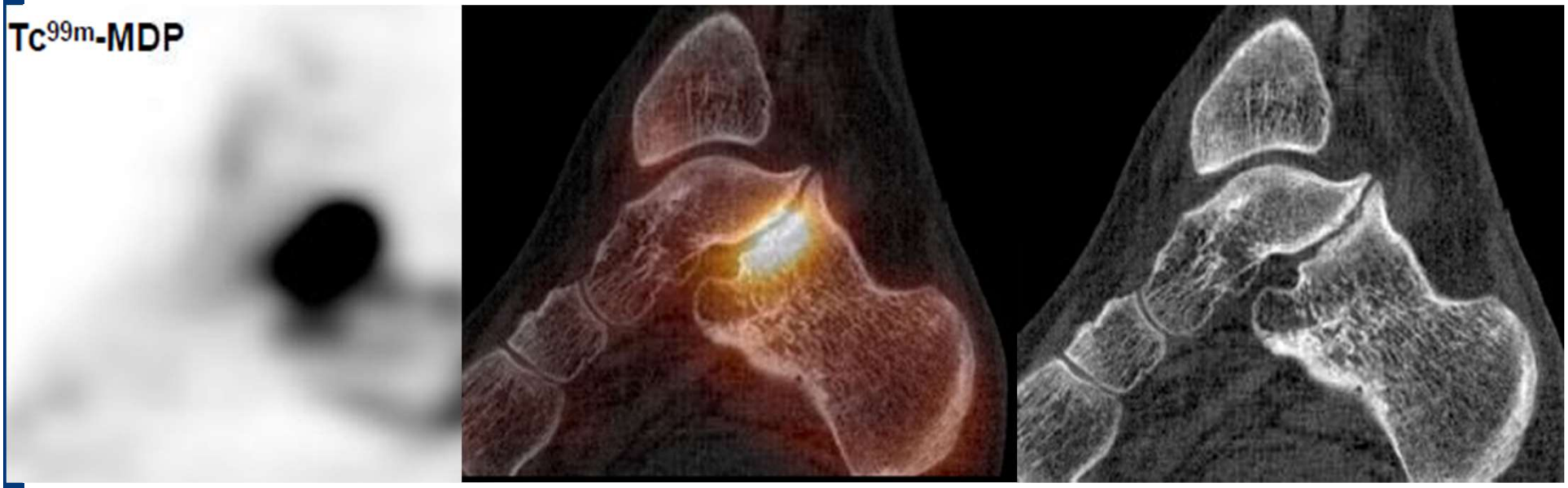

MARIA MIDDELARES

Talocalcaneale coalitie

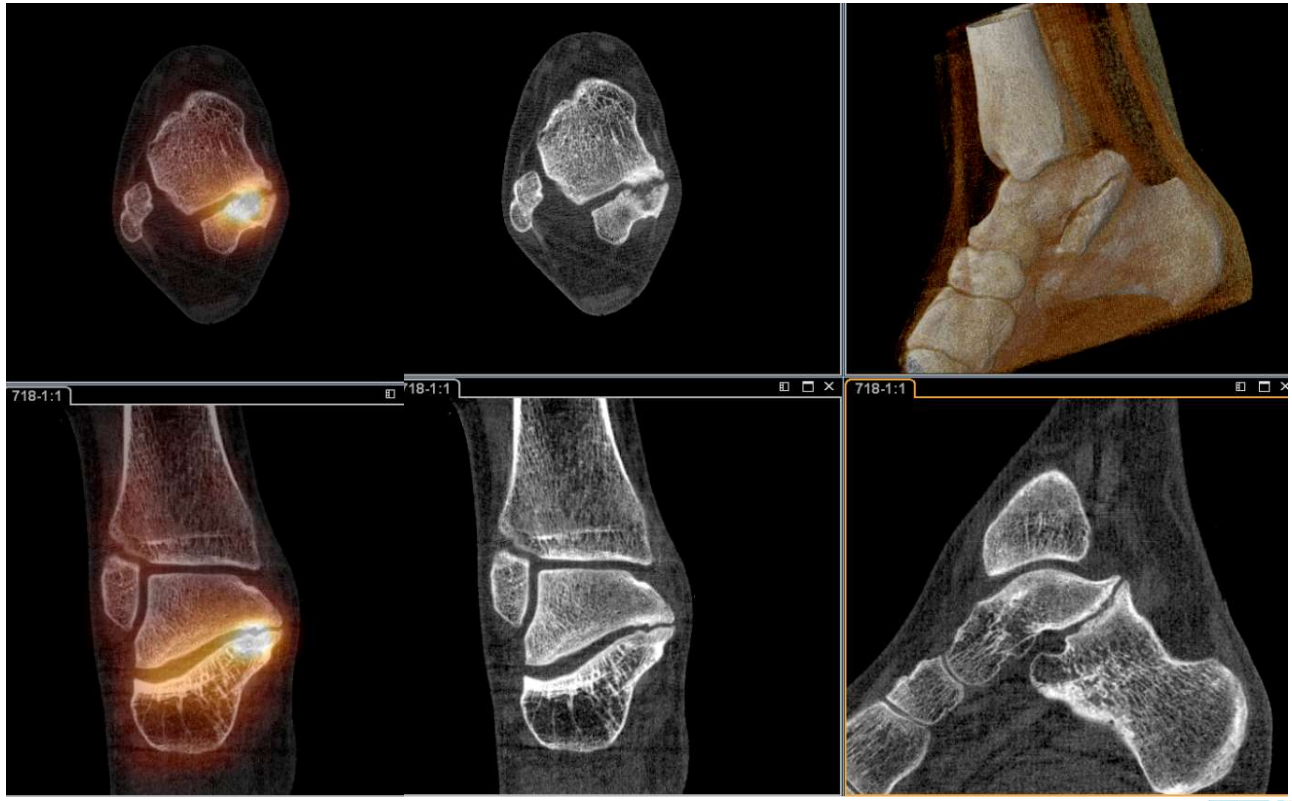

MARIA MIDDELARES

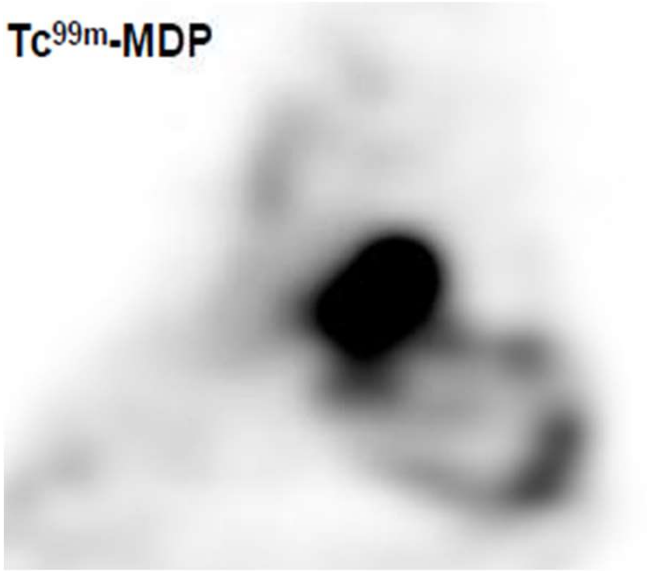

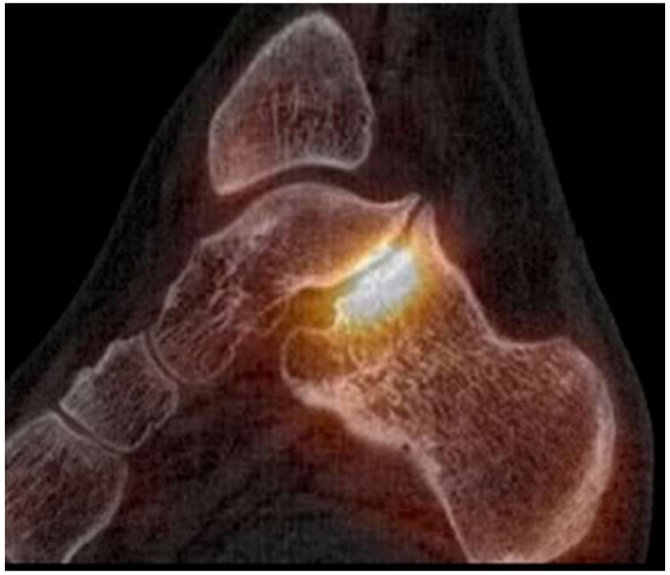

MARIA MIDDELARES



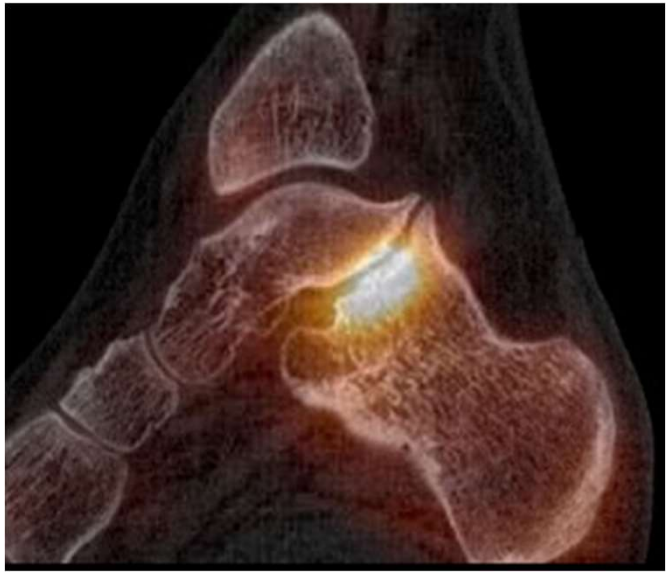

MARIA MIDDELARES


Tc99m-MDP

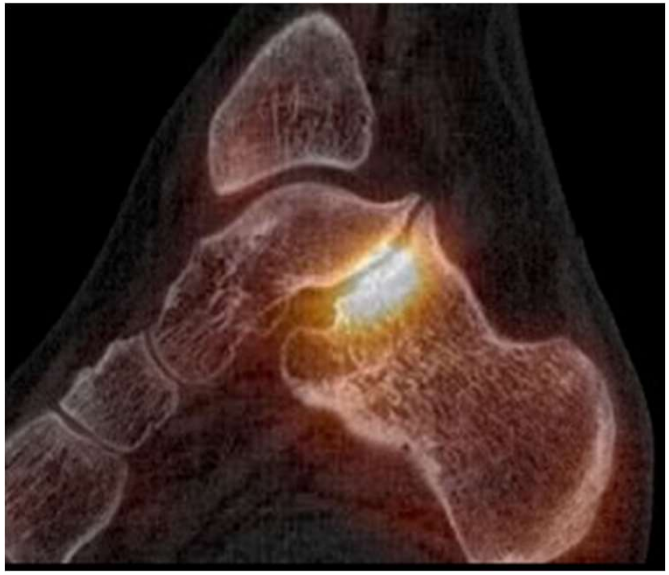

VIJFTIG
TINTEN GRIJS
NU VERFILMD
E L JAMES
PROMETHEUS

KS
ARIA
DDELARES

♀, 57j., pijn aan de achtervoet



MARIA MIDDELARES

Degeneratief subtalair lijden

MARIA MIDDELARES

Osteoartrose

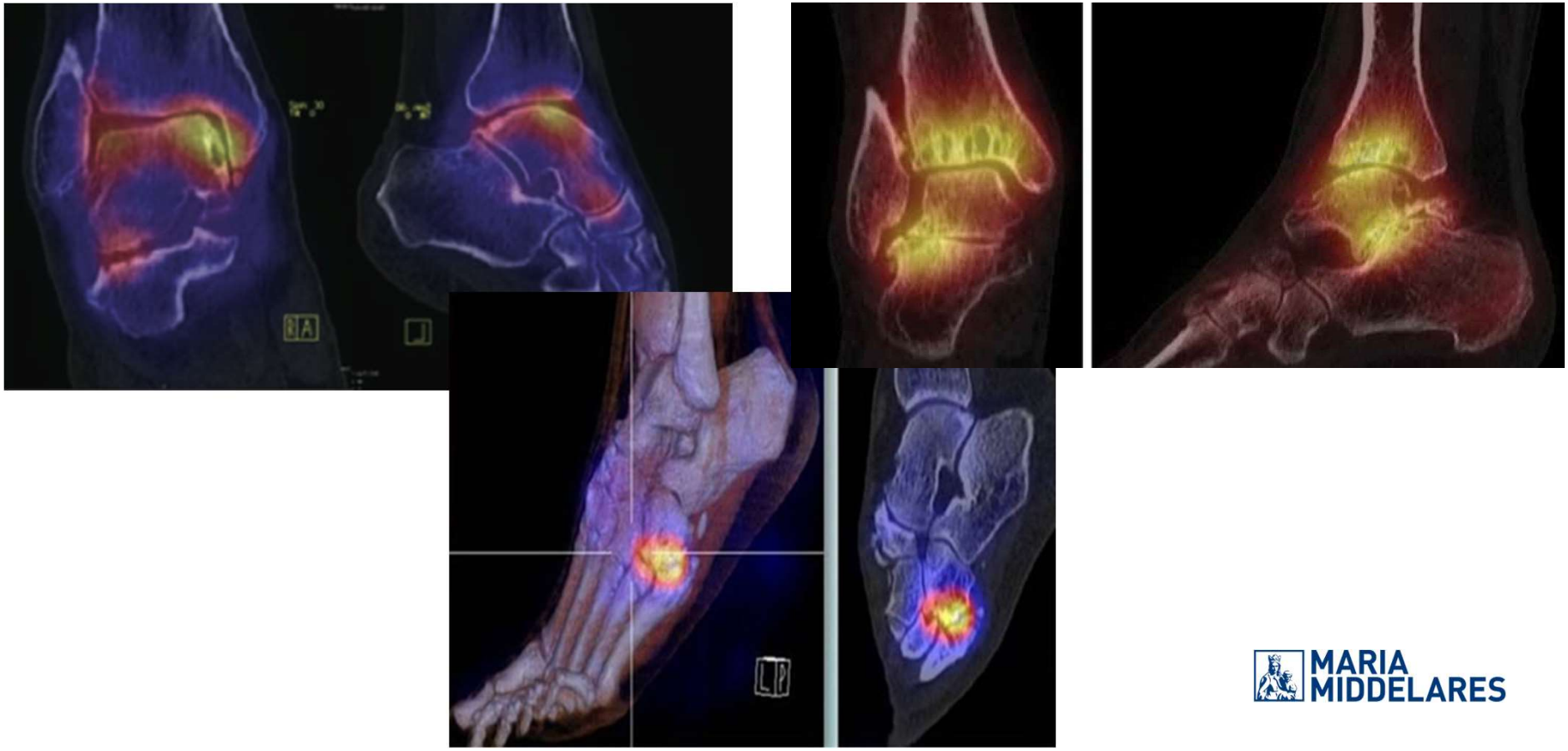

MARIA MIDDELARES

Osteoartrose

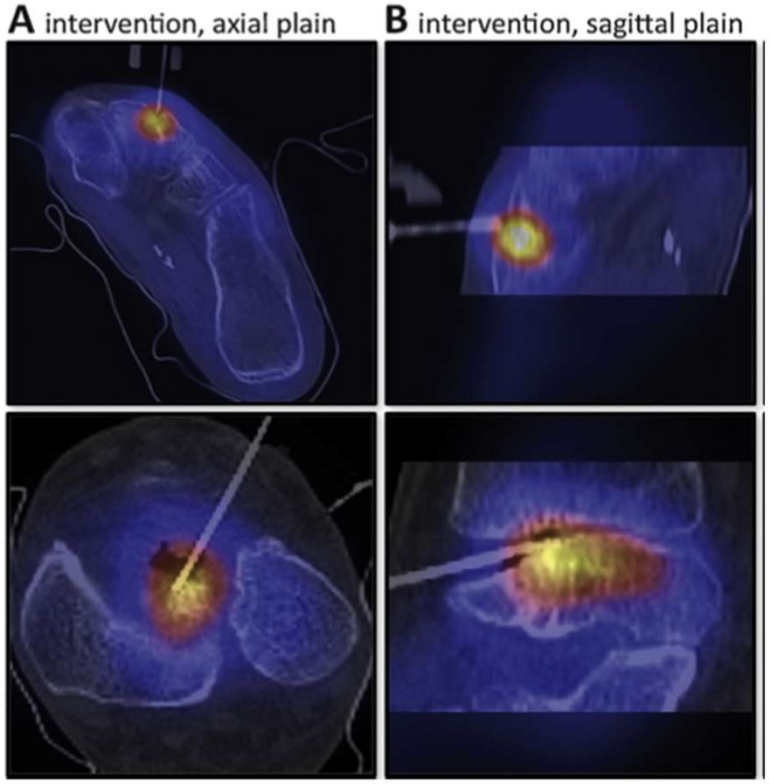

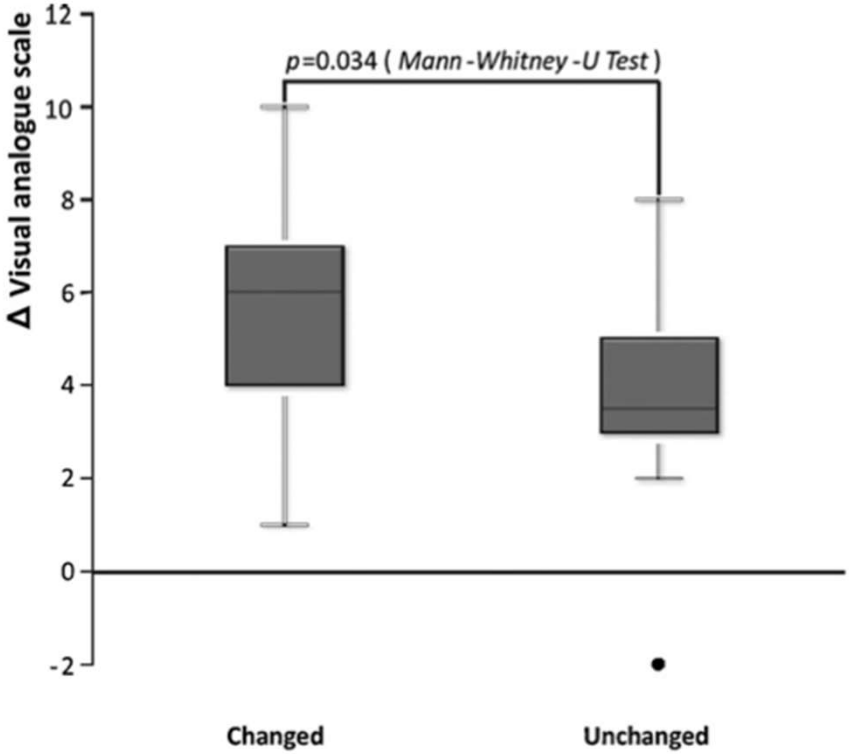

Kretzschmar et al., European Journal of Radiology, 2011

MARIA MIDDELARES

CMC versus STT

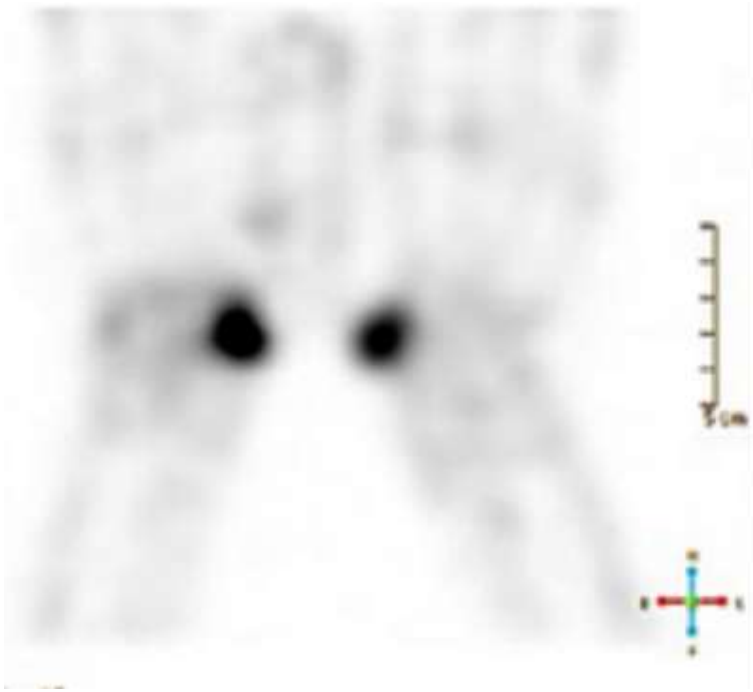

MARIA MIDDELARES

♀, 55j., initieel kniepijn links, later polyarthralgieën

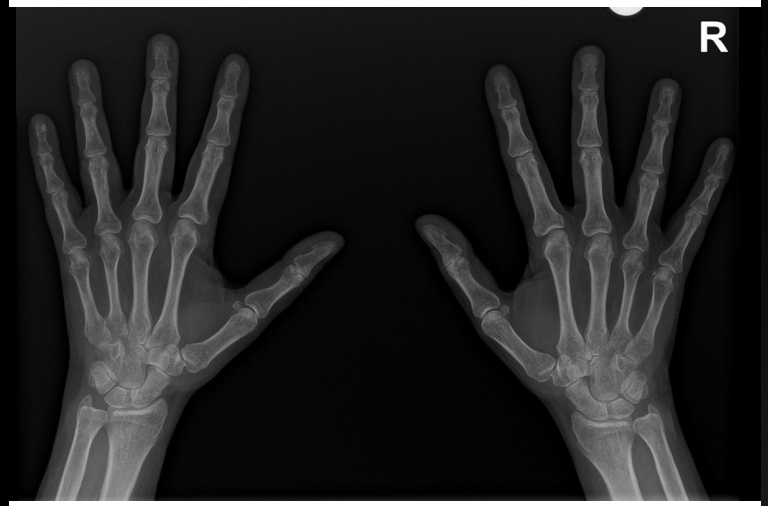

MARIA MIDDELARES

♀, 55j., initieel kniepijn links, later polyarthralgieën

MARIA MIDDELARES

Psoriasis artritis

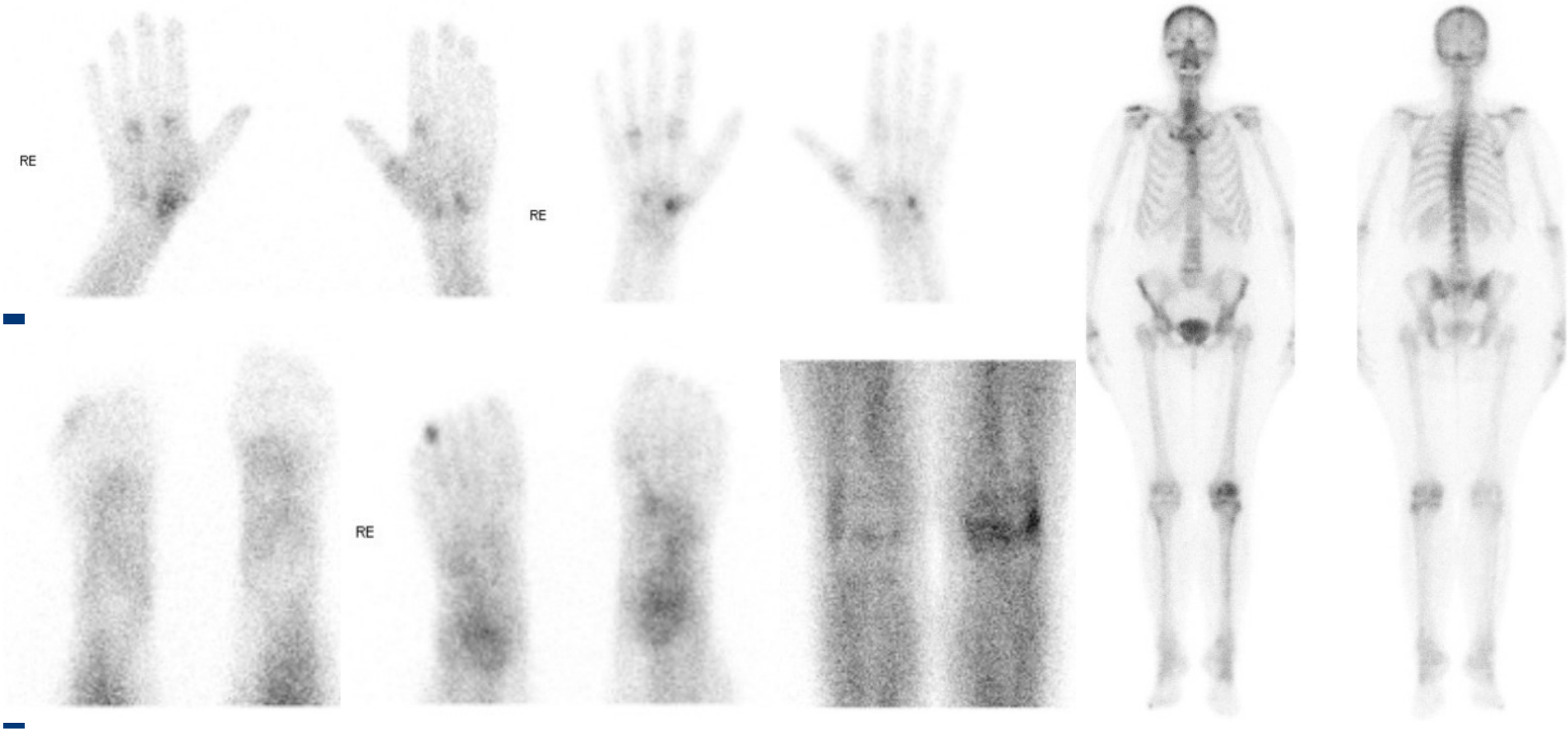

Psoriasis artritis

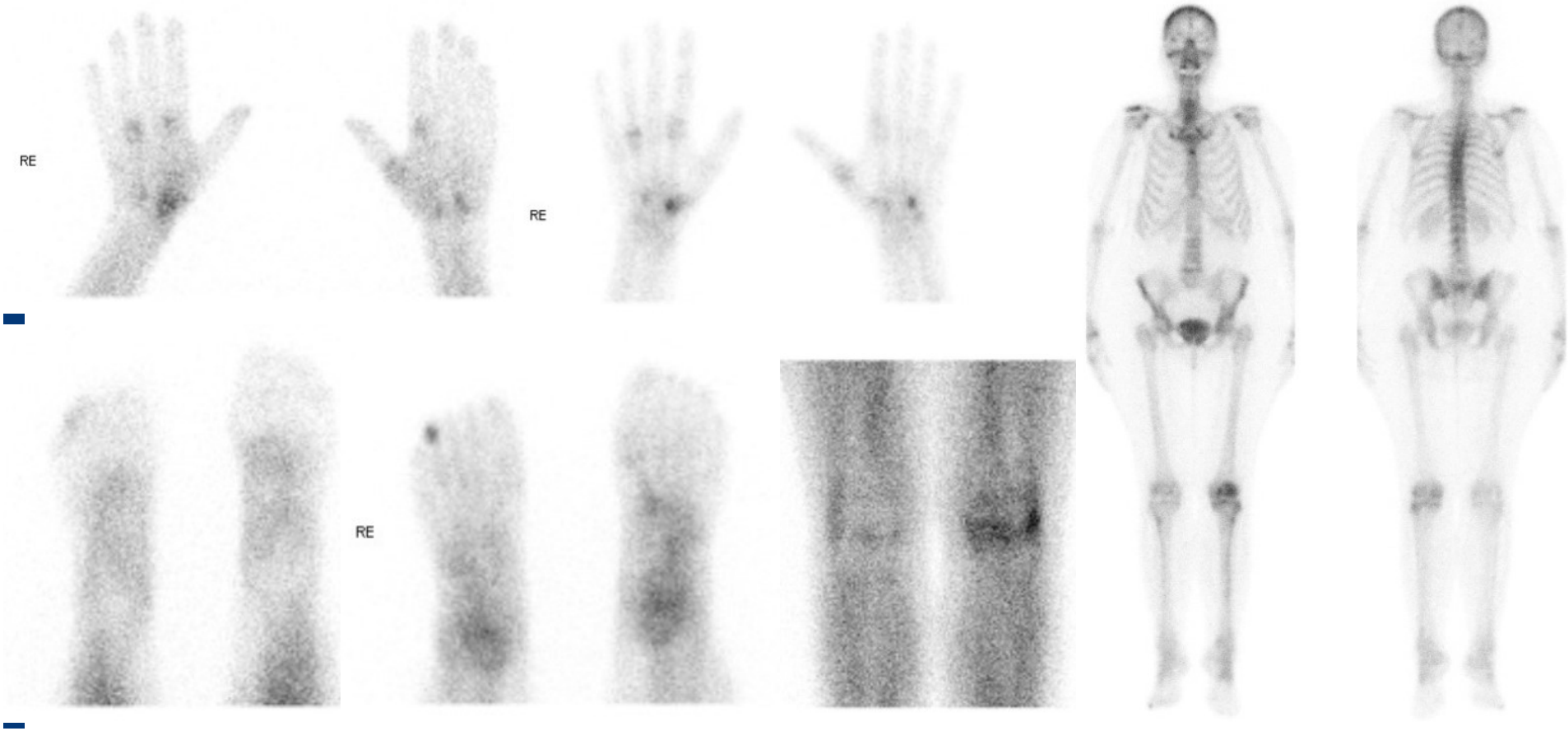

Psoriasis artritis

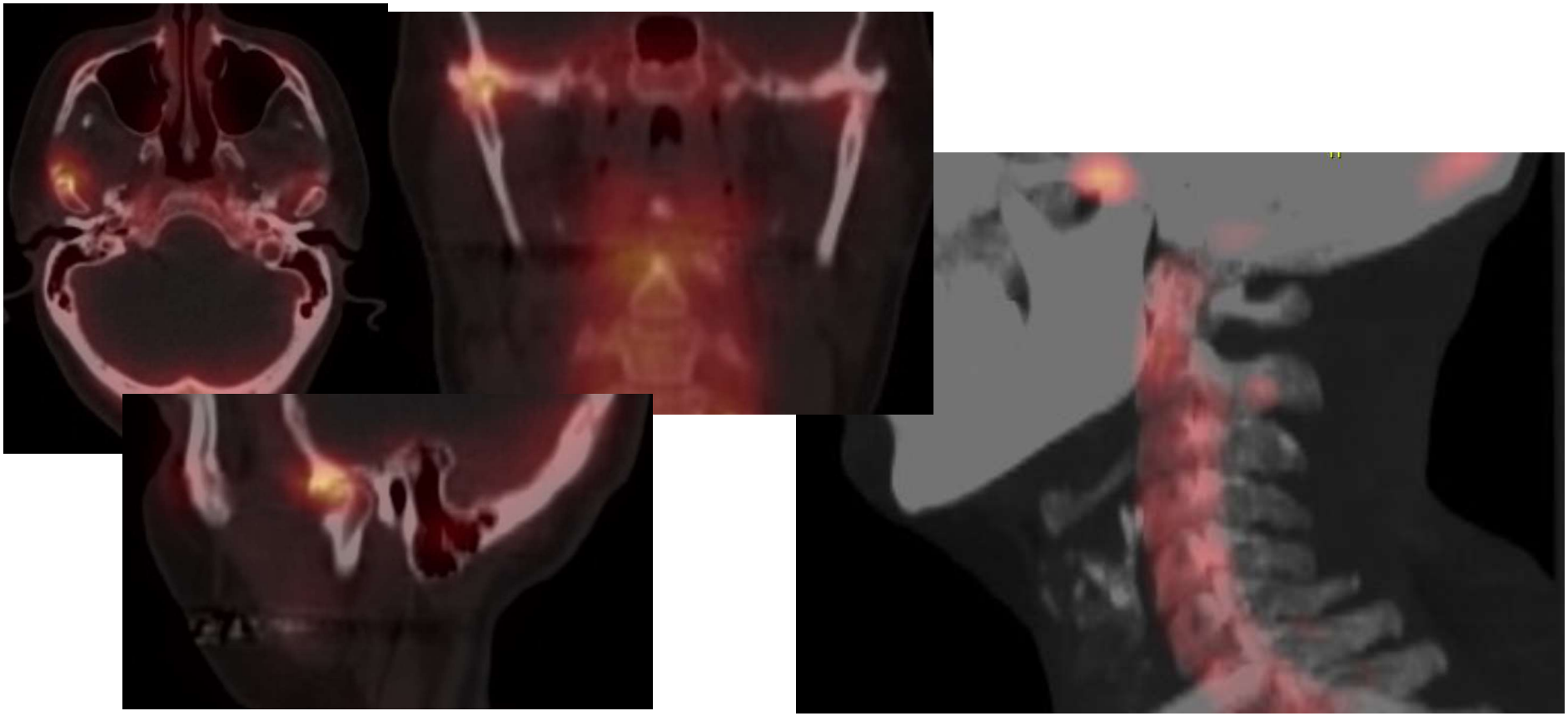

♂, 41j., pijn middenvoet

Stressfractuur basis MT-II

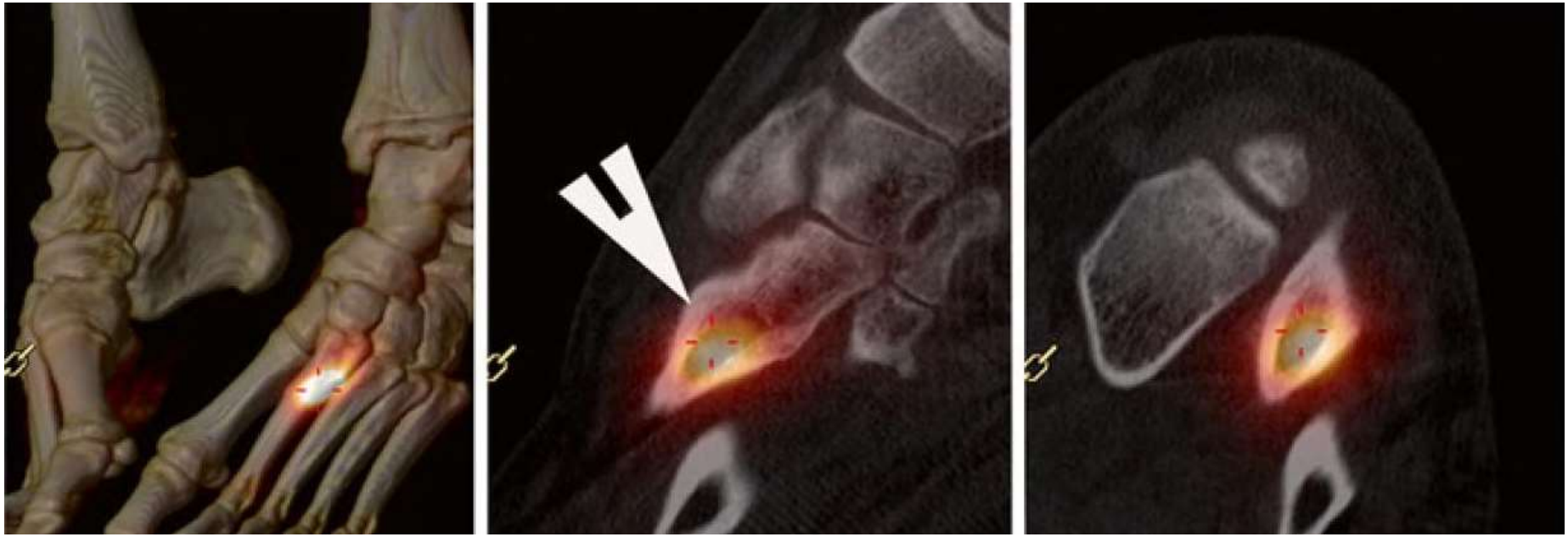

MARIA MIDDELARES

Posttraumatische pathologie

MARIA MIDDELARES

♂, 34j., duimlast na trauma, initiële rx negatief

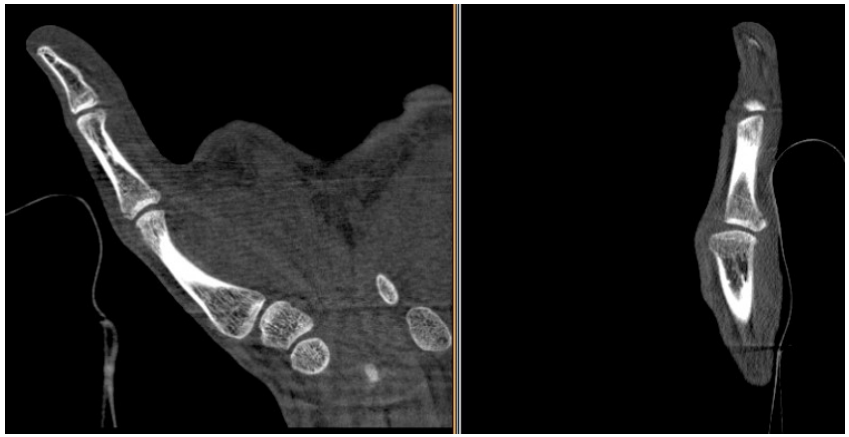

MARIA MIDDELARES

♂, 34j., duimlast na trauma, initiële rx negatief

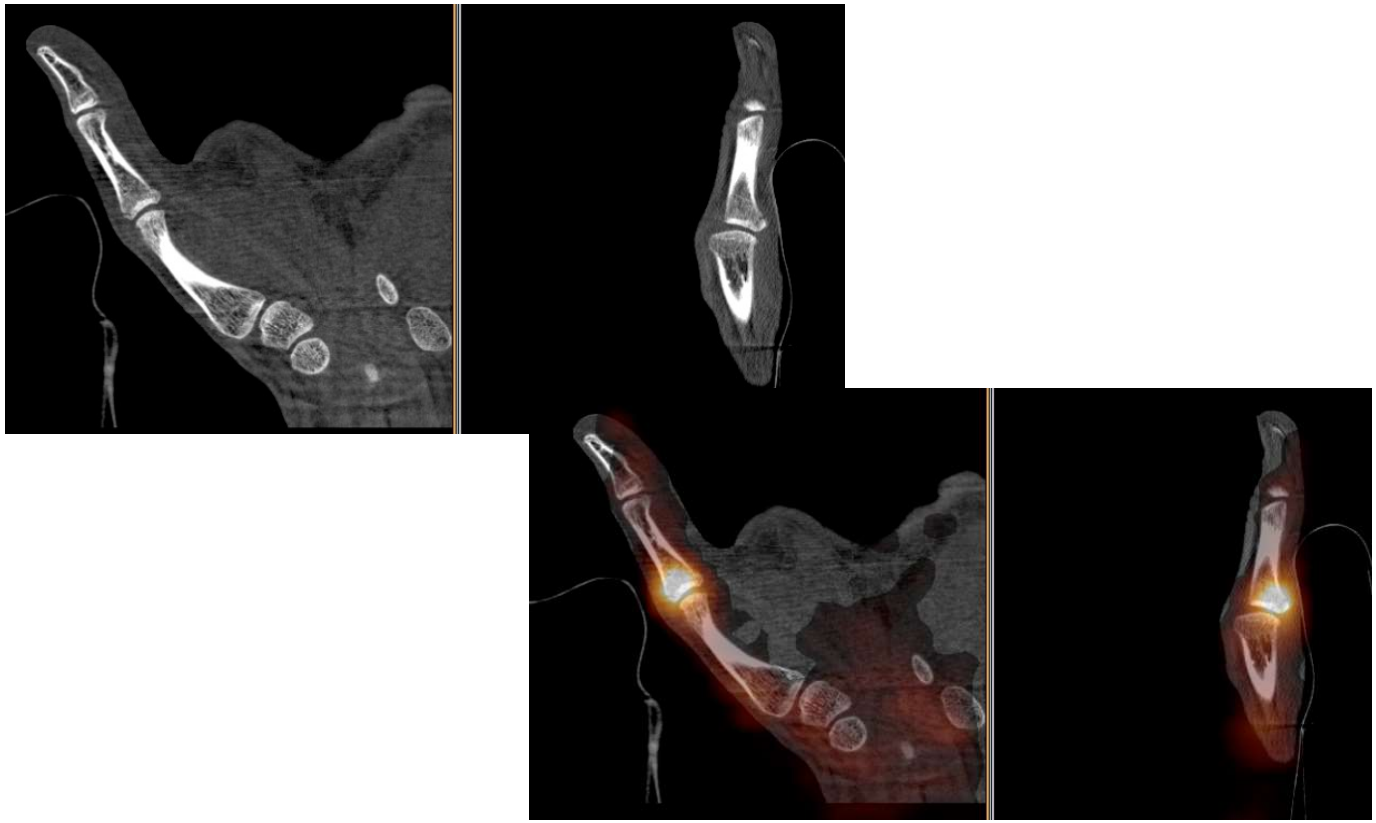

MARIA MIDDELARES

Occulte fractuurhaard

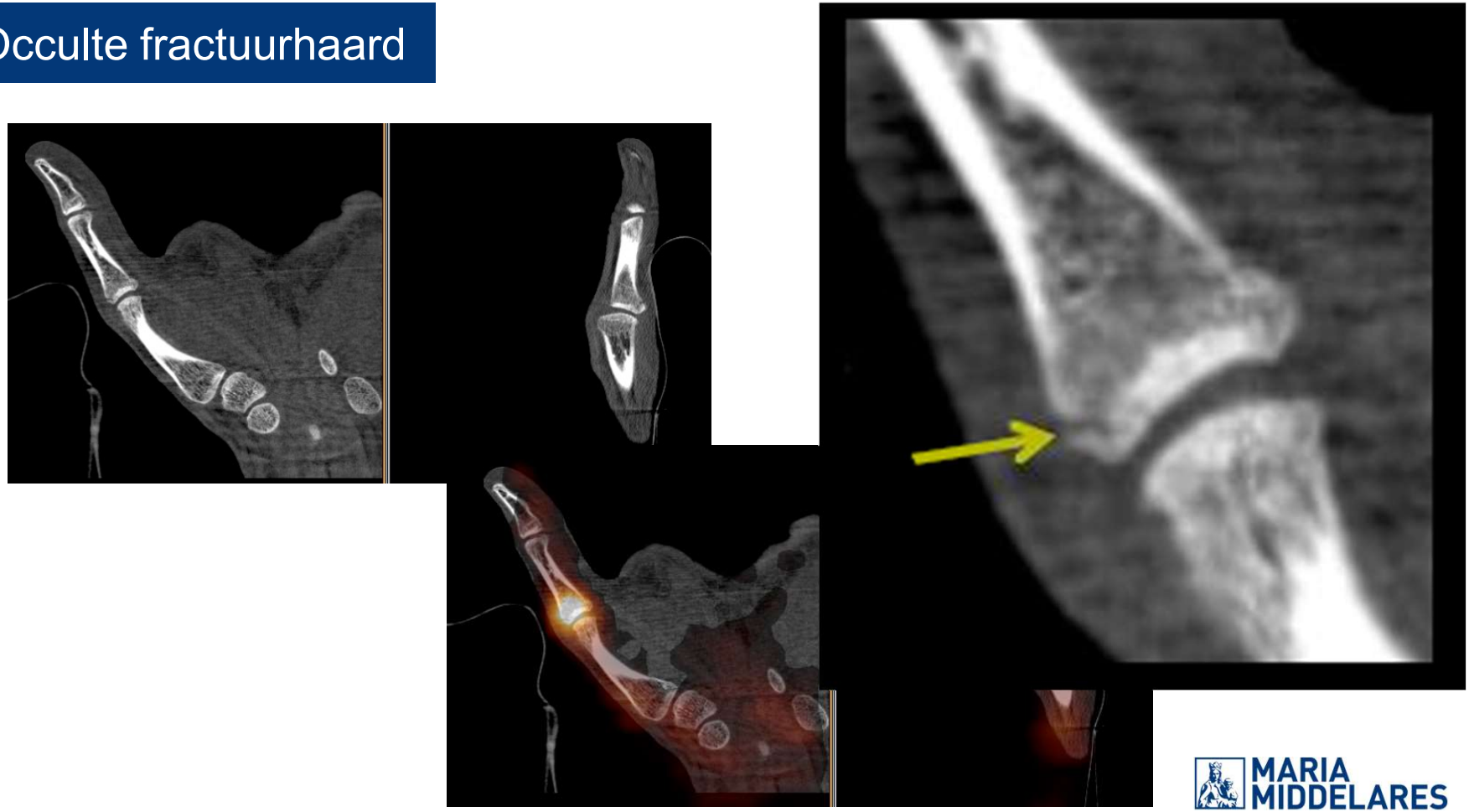

MARIA MIDDELARES

♀, 24j., rugpijn

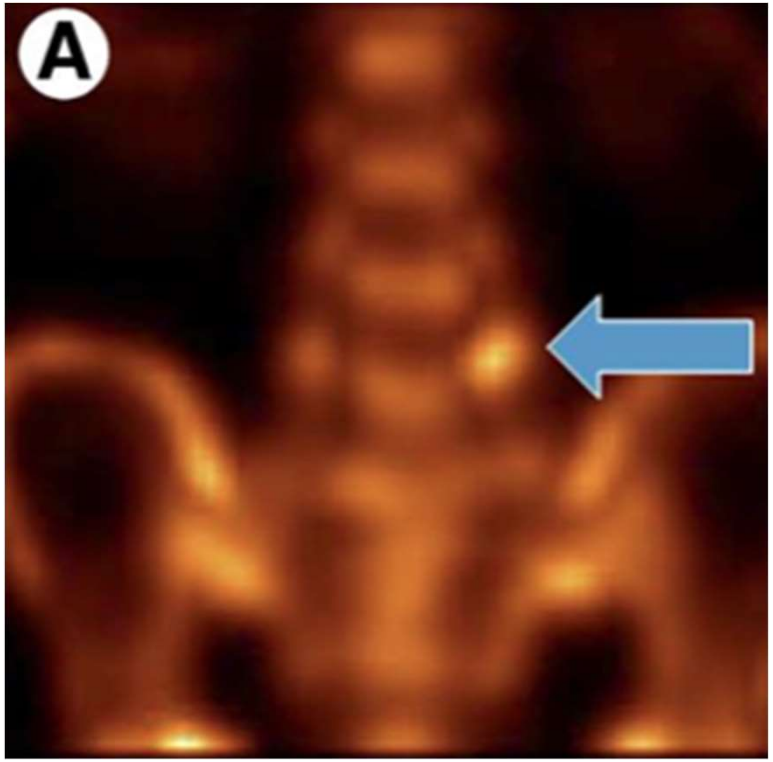

MARIA MIDDELARES

♀, 24j., rugpijn, balletdanseres

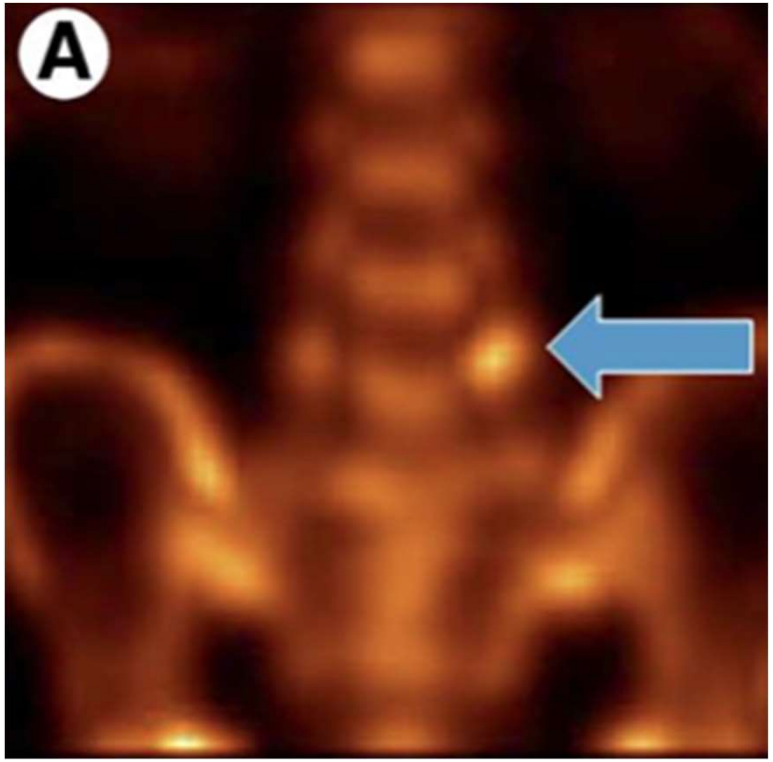

MARIA MIDDELARES

Acute spondylolyse

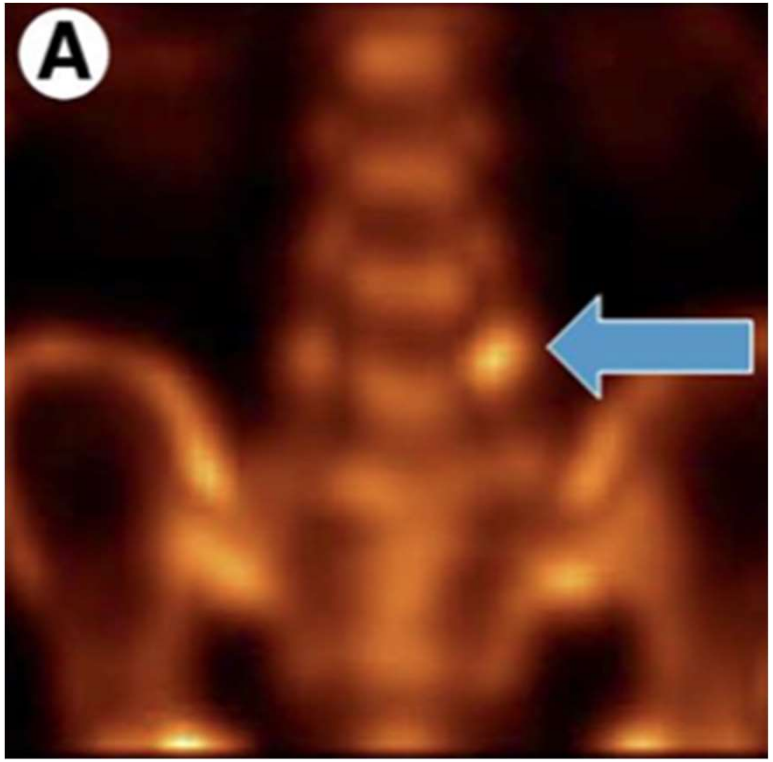

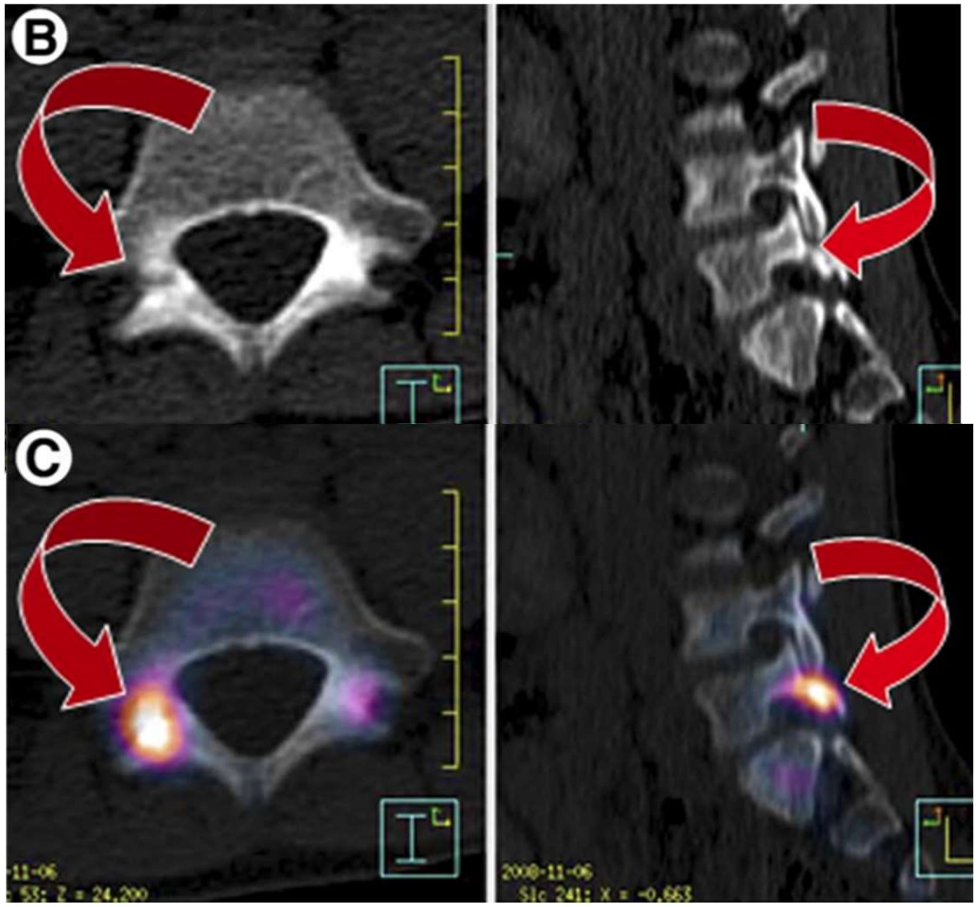

MARIA MIDDELARES

♀, 64j., persisterende ruglast 8 m na indeuking Th11

MARIA MIDDELARES

Actief facetlijden Th10-Th11 rechts na indeuking Th11

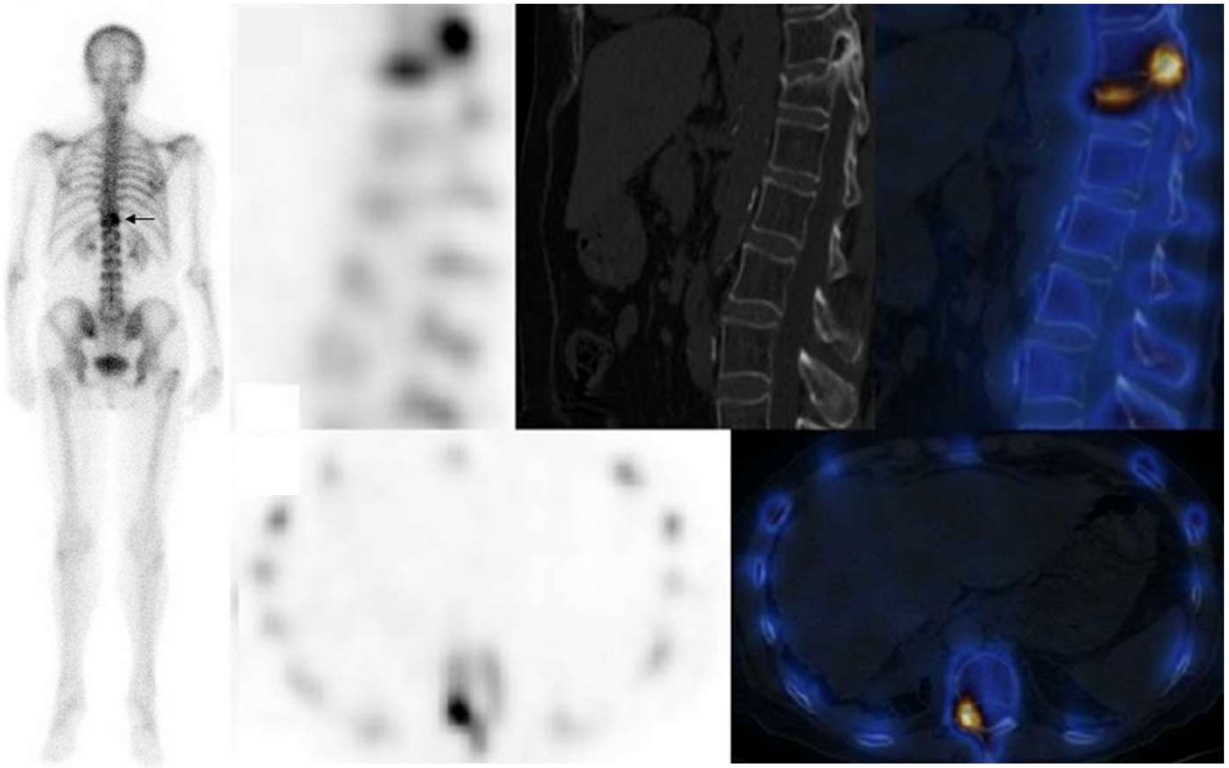

MARIA MIDDELARES

SPECT-CT bij facetlijden

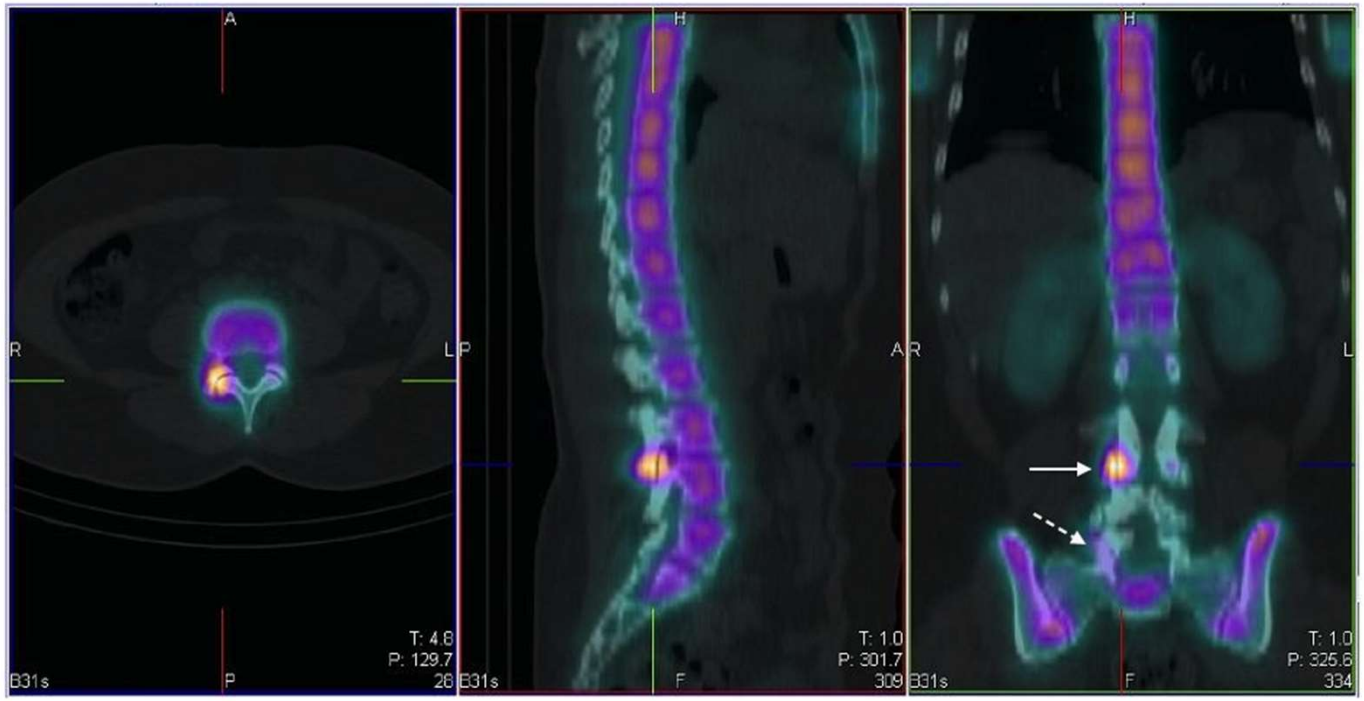

MARIA MIDDELARES

SPECT-CT bij facetlijden

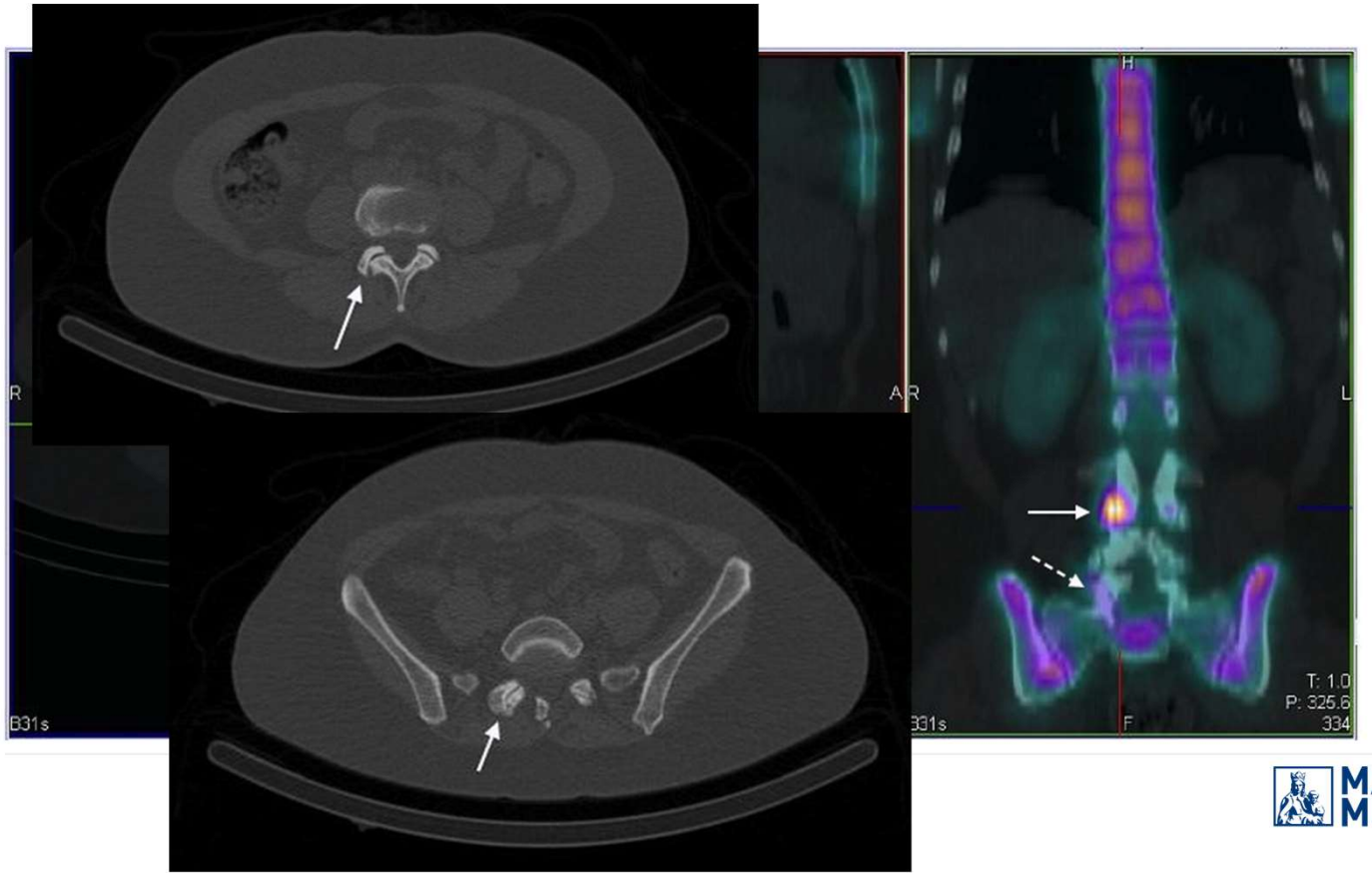

MARIA MIDDELARES

SPECT-CT bij facetlijden

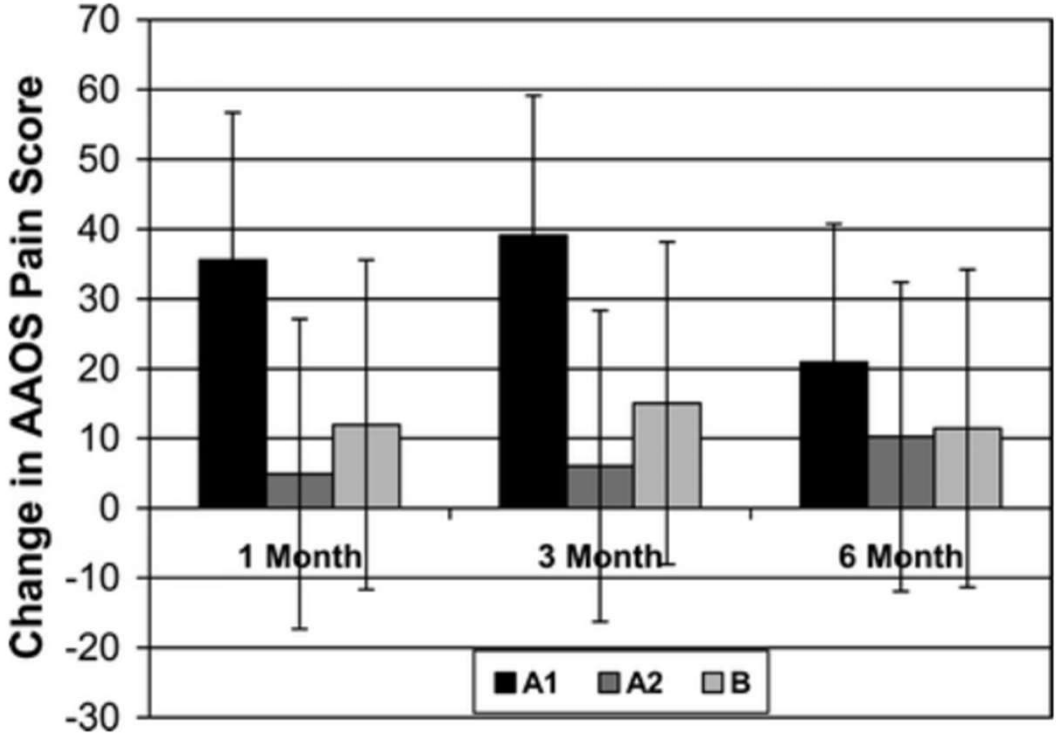

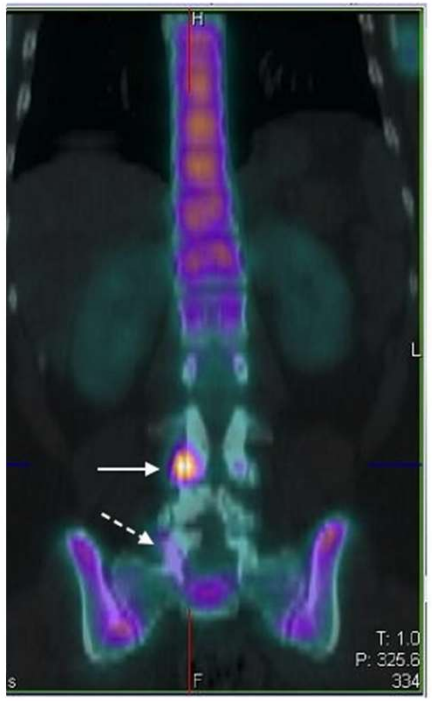

Pneumaticos et al., Radiology 2006;238:693–8

MARIA MIDDELARES

♀, 64j., recidief ruglast na PLIF L5-S1

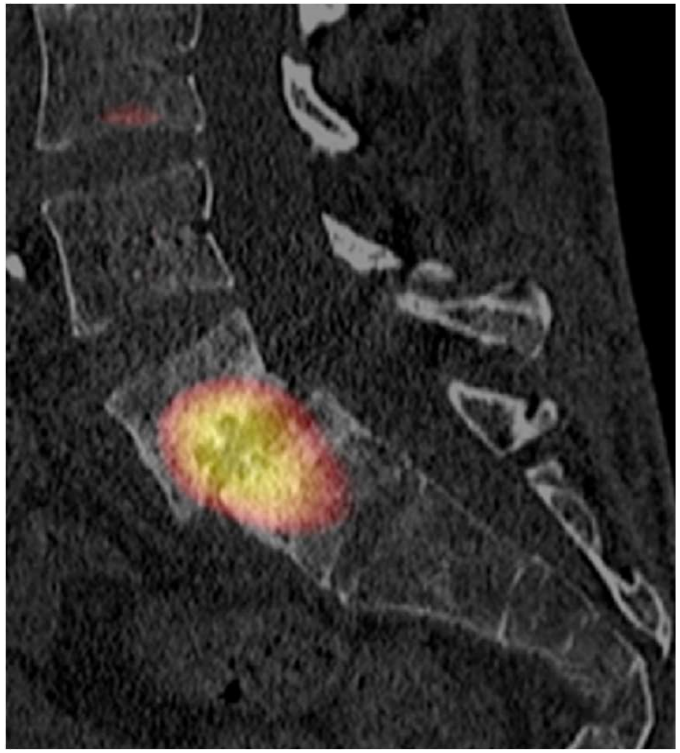

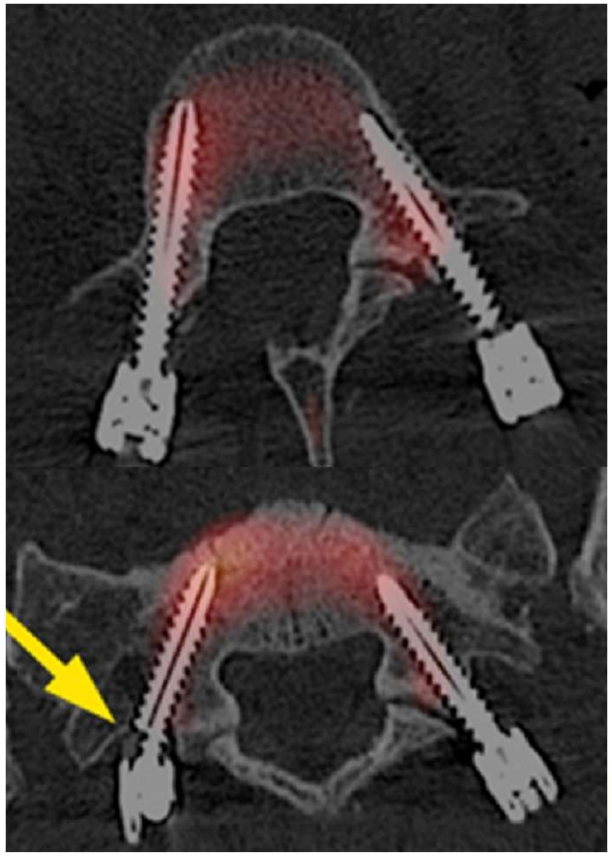

MARIA MIDDELARES

SPECT-CT na fusiechirurgie

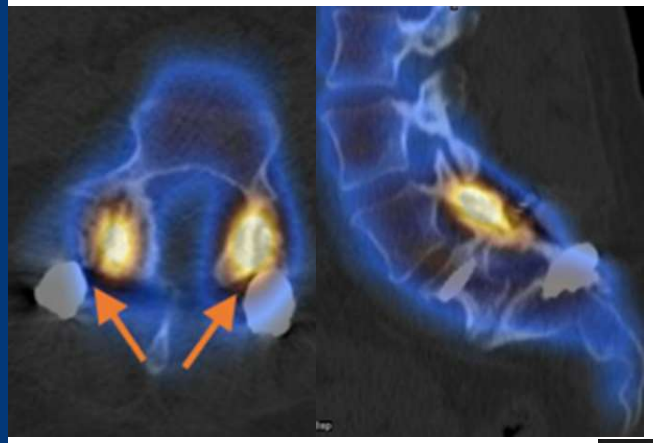

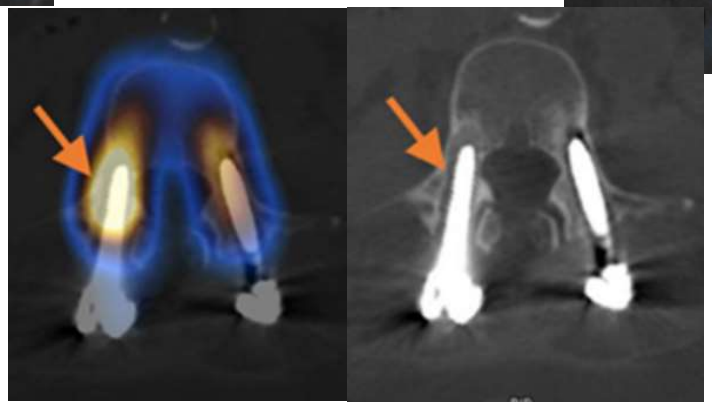

MARIA MIDDELARES

Al-Riyami, K., Gnanasegaran, G., Van den Wyngaert, T. et al. Eur J Nucl Med Mol Imaging (2017) 44: 2094. https://doi.org/10.1007/s00259-017-3765-6

♂, 71j., pijn in de lies 7j. na THP rechts, initiële rx negatief

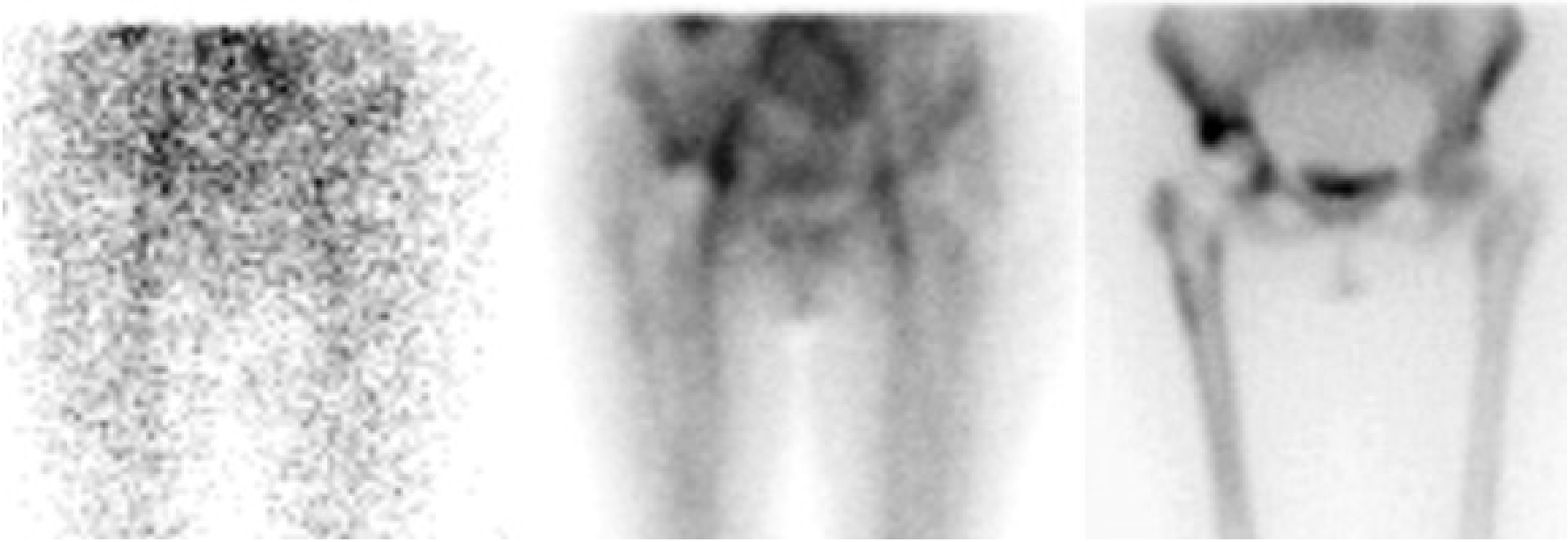

MARIA MIDDELARES

Acetabulaire loosening

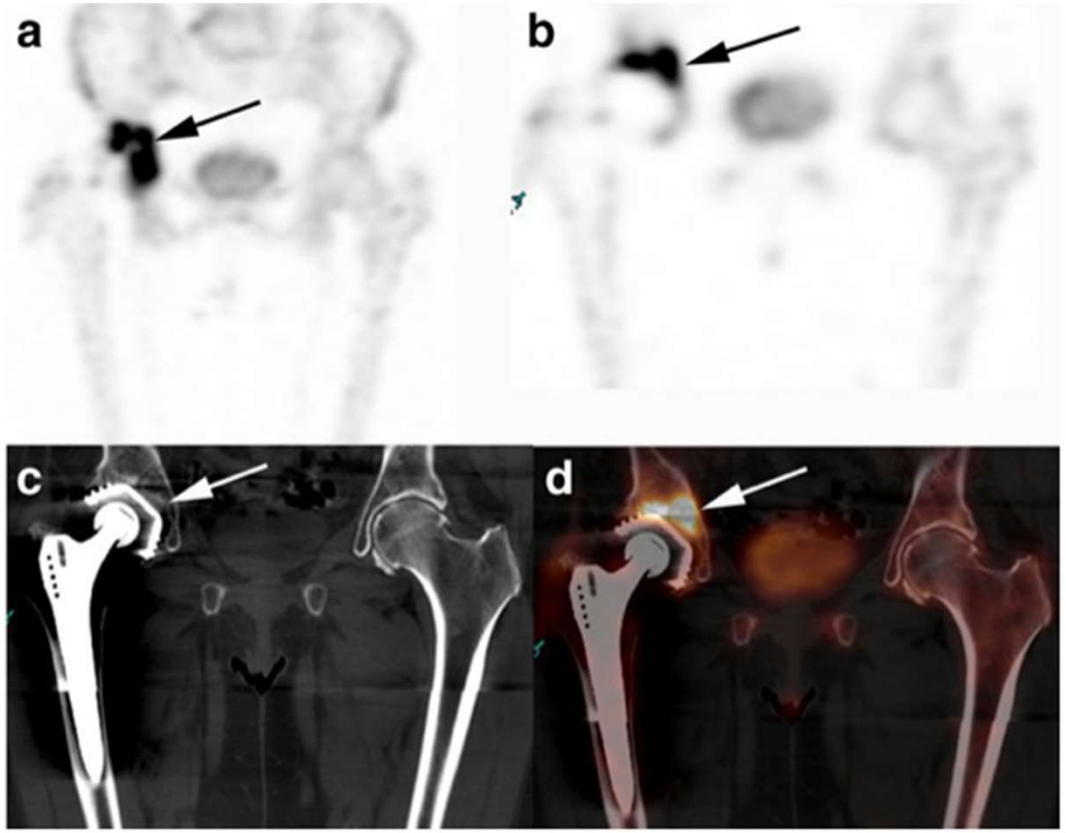

MARIA MIDDELARES

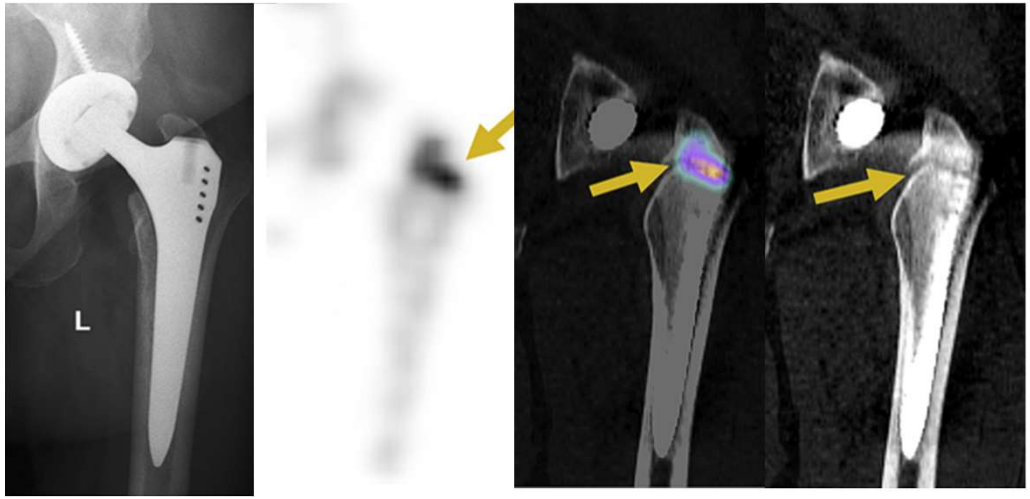

Periprothetische fractuurhaard

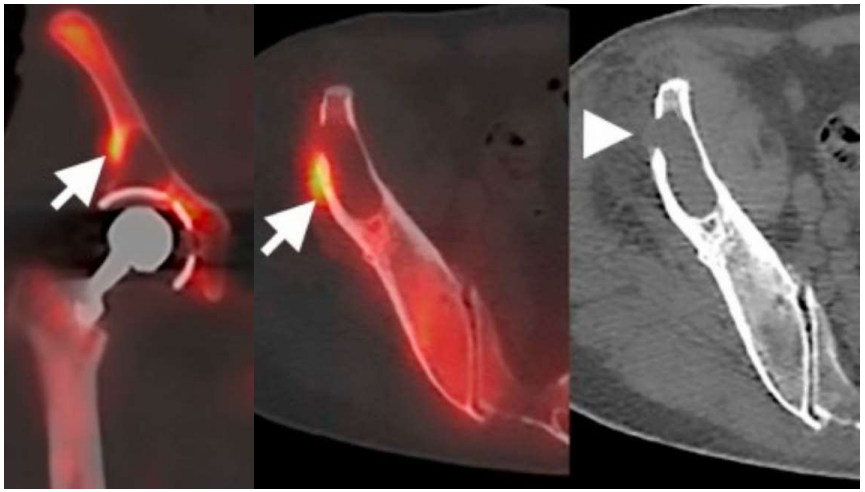

Polyethyleenslijtage + granuloomvorming

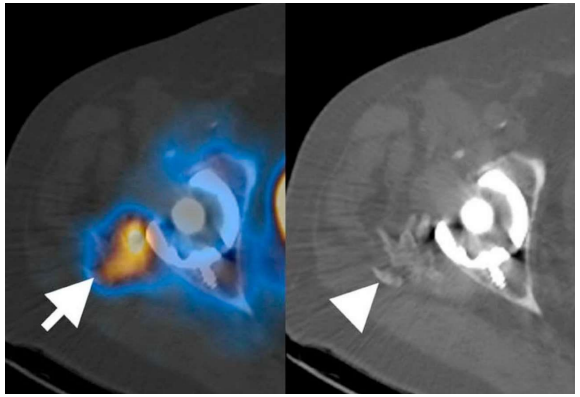

PAO na THP

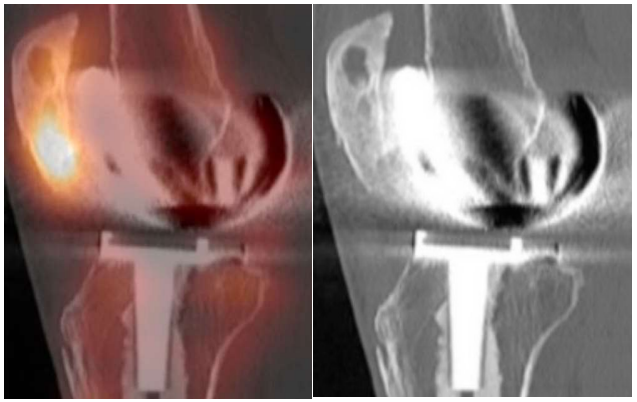

PF lijden na TKP

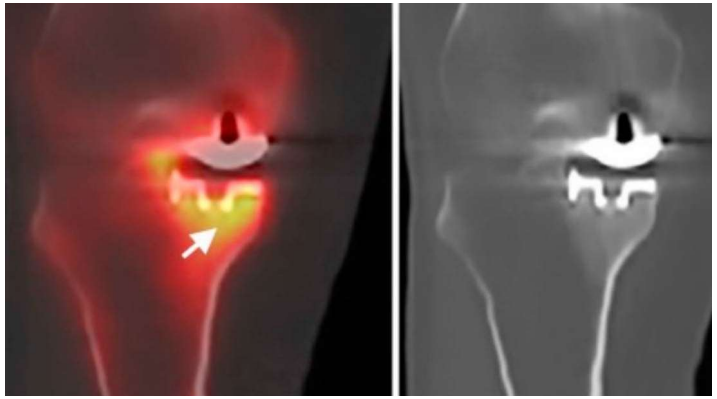

Tibiale loosening UKP

SPECT-CT na artrodese / TEP

Pseudartrose na talonaviculaire artrodese

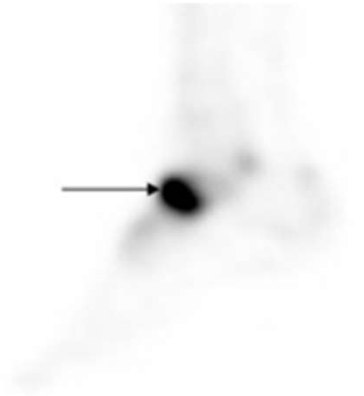

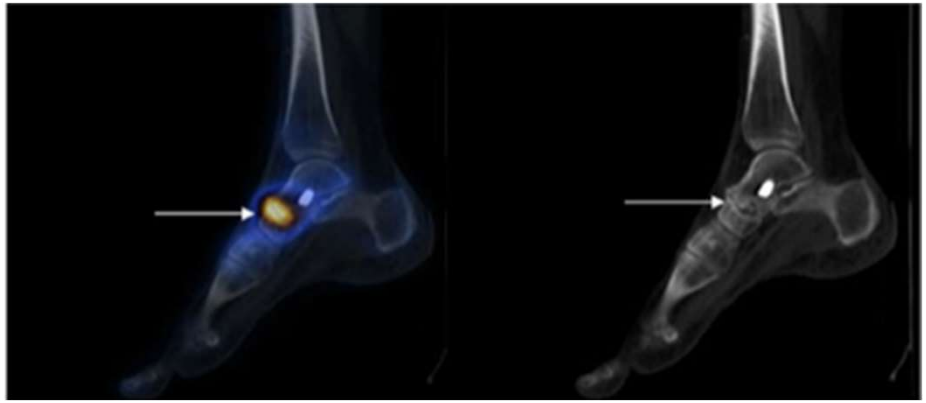

Lateraal impingement na TEP

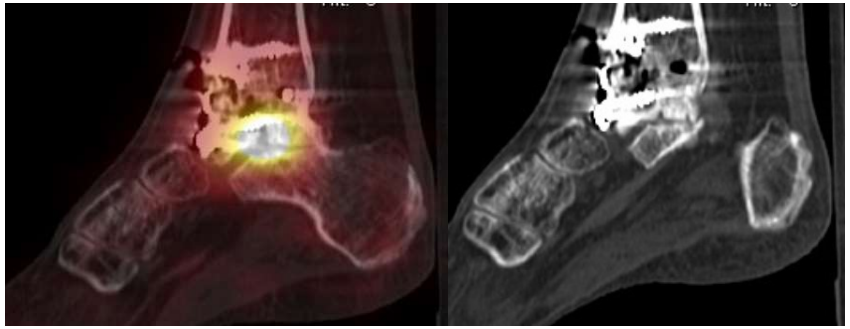

Subtalair lijden na tibiotalaire artrodese

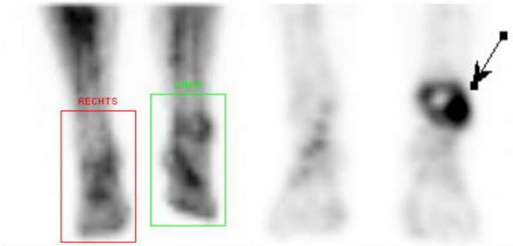

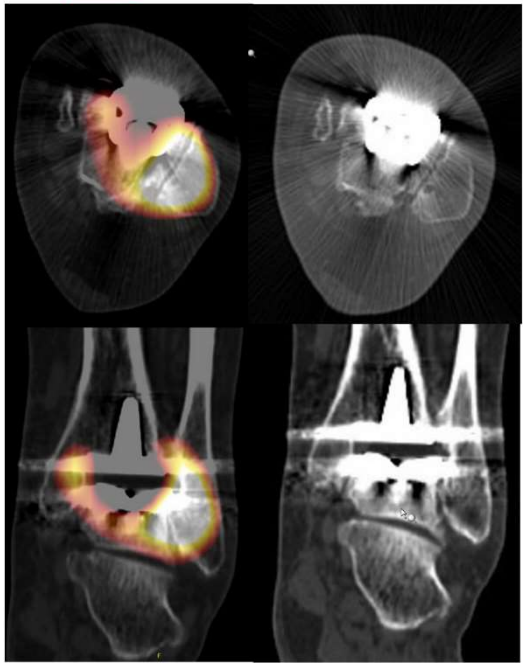

MARIA MIDDELARES

De geïnfecteerde prothese

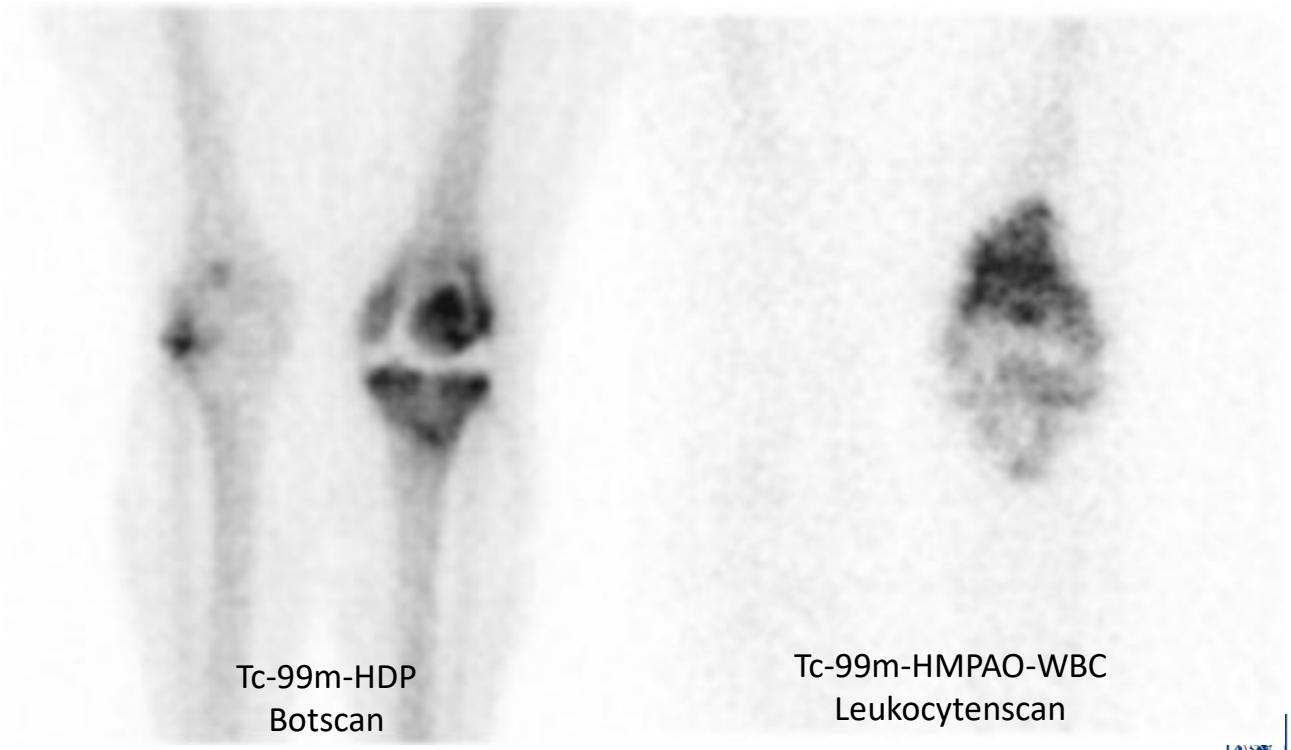

MARIA MIDDELARES

Leukocytenscan: laattijdige beeldvorming

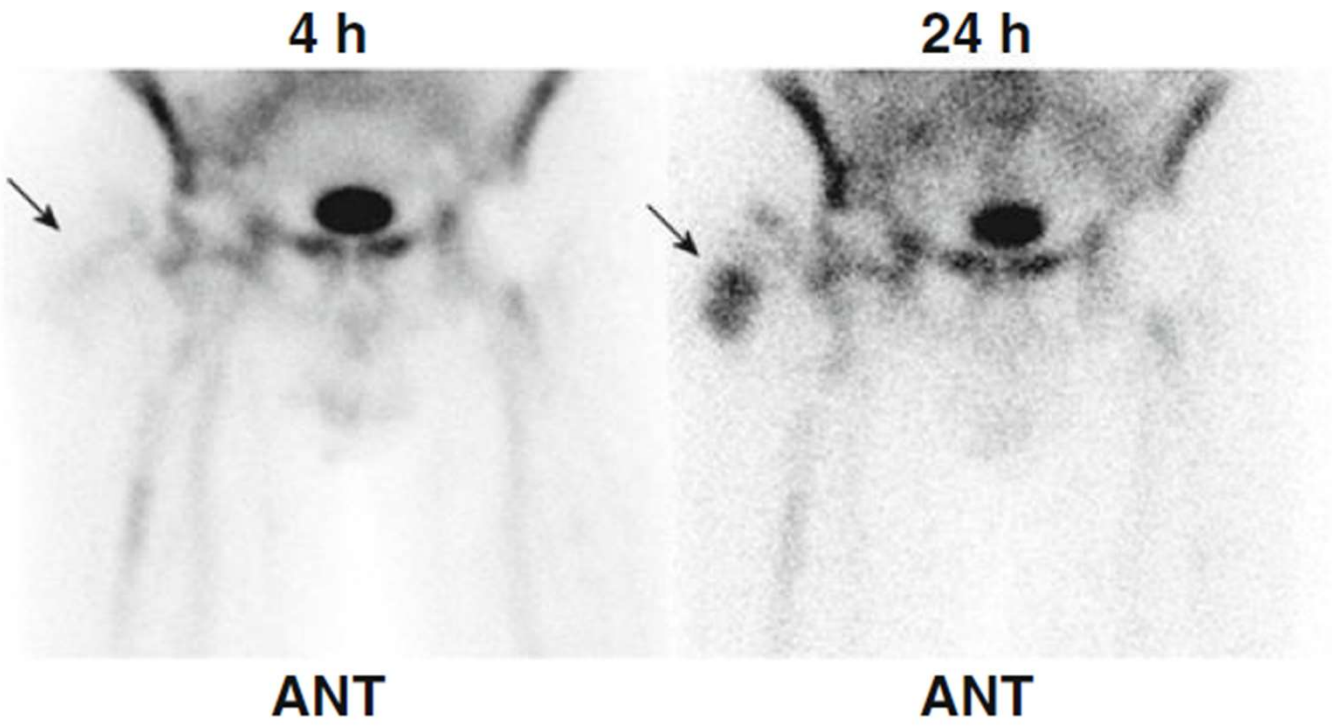

MARIA MIDDELARES

SPECT-CT en leukocytenscans

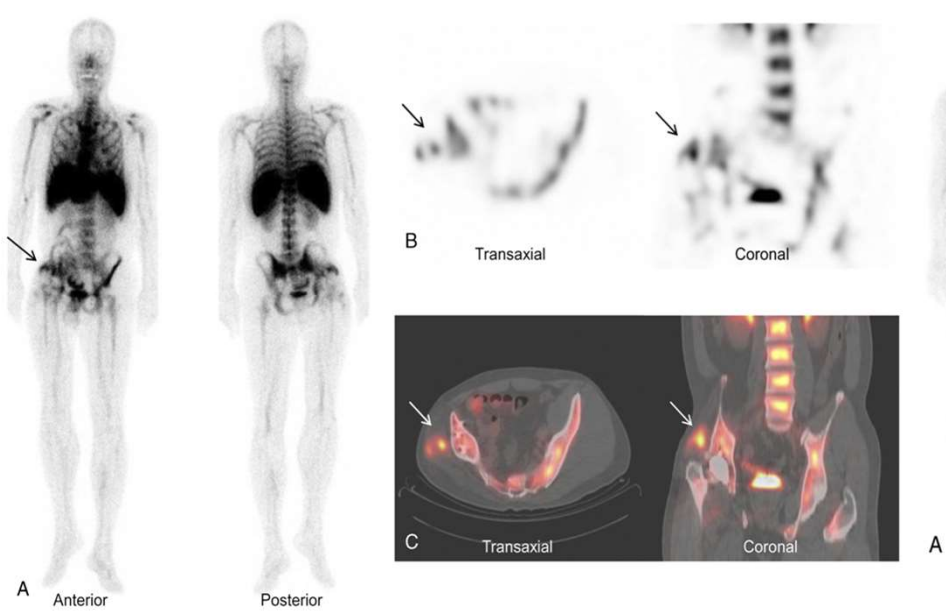

Gluteale weke delen infectie

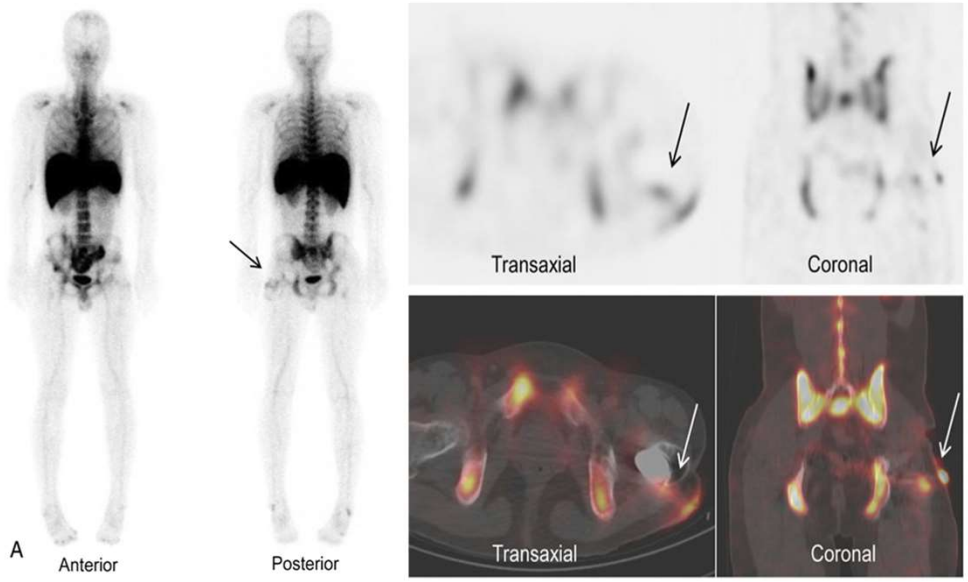

Fisteltraject naar THP links

MARIA MIDDELARES

SPECT-CT in oncologie

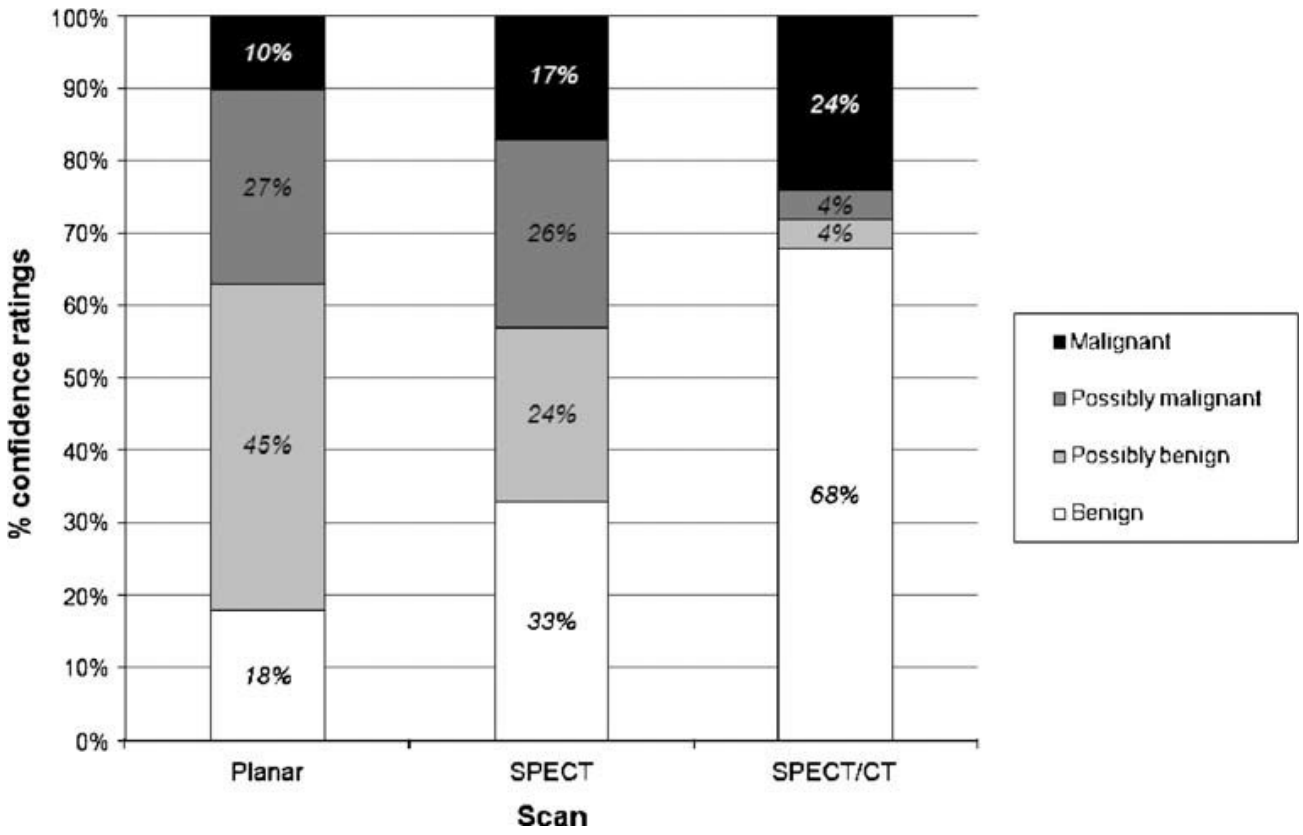

Helyar et al., Eur J Nucl Med Mol Imaging (2010) 37:706–713

MARIA MIDDELARES

Staging prostaatcarcinoom

MARIA MIDDELARES

Staging prostaatcarcinoom

MARIA MIDDELARES

Botmetastase L1

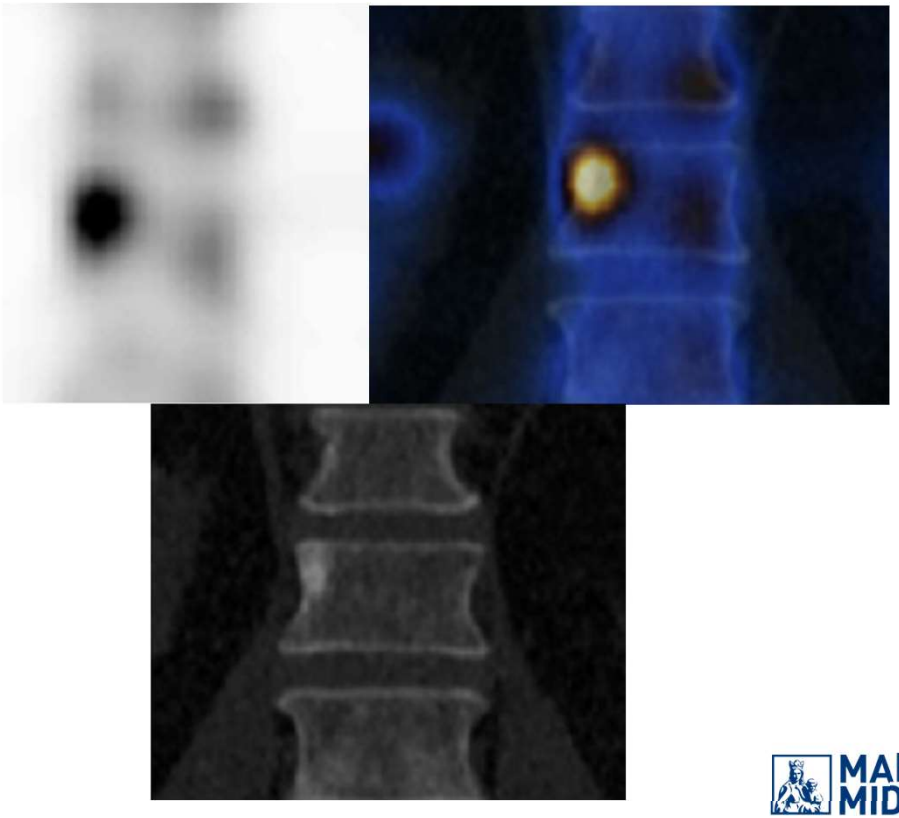

MARIA MIDDELARES

Staging prostaatcarcinoom

MARIA MIDDELARES

Degeneratieve discopathie L2-L3

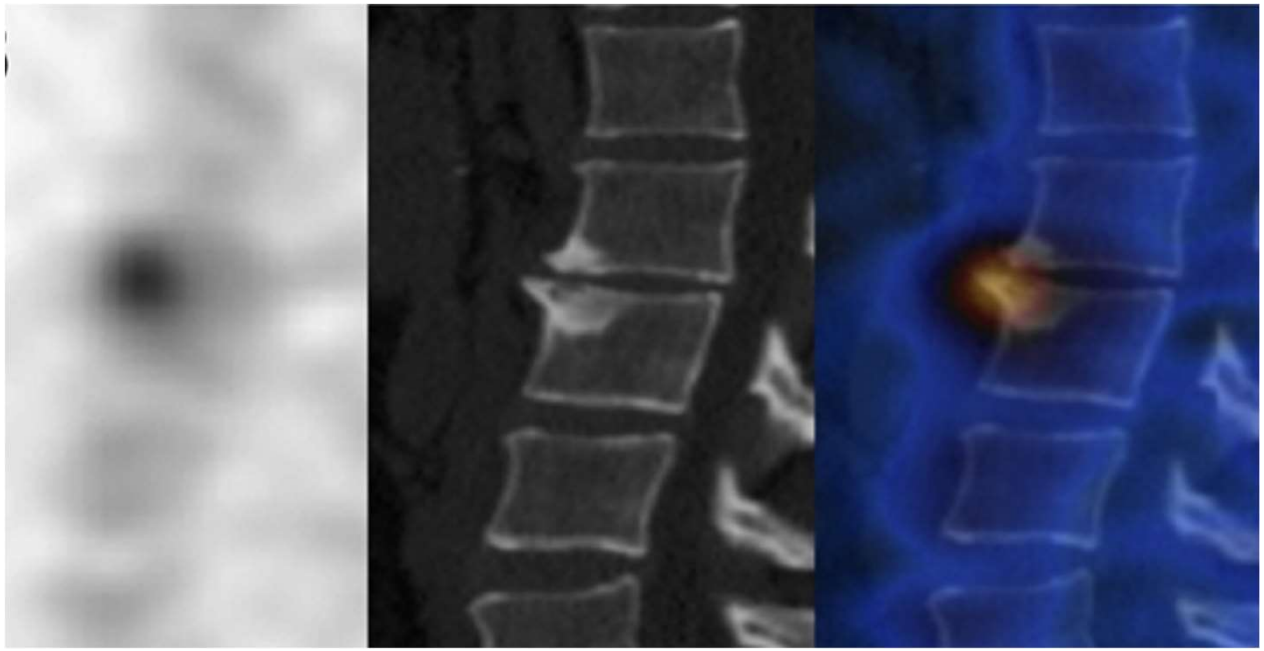

MARIA MIDDELARES

En PET-CT?

Hofman, Michael S. "Fluorodeoxyglucose positron emission tomography/computed tomography: a “one stop shop” for diagnosing polymyalgia rheumatica." Bmj 348 (2014): f7705.

MARIA MIDDELARES

PET-CT bij spondylodiscitis

Infection (2017) 45:41–49
DOI 10.1007/s15010-016-0914-y

ORIGINAL PAPER

A comparison of the diagnostic value of MRI and ^{18}F-FDG-PET/CT in suspected spondylodiscitis

Carolijn Smids[1] · Ilse J. E. Kouijzer[1] · Fidel J. Vos[1,2] · Tom Sprong[3] · Allard J. F. Hosman[4] · Jacky W. J. de Rooy[5] · Erik H. J. G. Aarntzen[5] · Lioe-Fee de Geus-Oei[5,6,7] · Wim J. G. Oyen[5] · Chantal P. Bleeker-Rovers[1]

	≤ 14days of start of symptoms	>14 days of start of symptoms	Total
MRI	29	39	68
Sensitivity	50 (28.3–71.8)	82 (61.9–93.6)	67 (52.5–80.0)
Specificity	86 (42.2-97.6)	83 (51.6–97.4)	84 (60.4–96.4)
PPV	92 (61.5-98.6)	92 (73.0–98.7)	92 (77.5–98.2)
NPV	35 (14.3-61.7)	67 (38.4–88.1)	50 (31.9–68.1)
Accuracy	58 (40.0-76.0)	82 (69.9–94.1)	72 (61.3–82.7)
^{18}F-FDG-PET/CT	32	36	68
Sensitivity	96 (79.6–99.3)	96 (78.8–99.3)	96 (86.0–99.4)
Specificity	100 (58.9–100)	92 (61.5–98.6)	95 (73.9–99.1)
PPV	100 (85.6–100)	96 (78.8–99.3)	98 (88.9–99.7)
NPV	88 (47.4–97.9)	92 (61.5–98.6)	90 (68.3–98.5)
Accuracy	97 (91.1–100)	94 (86.2–100)	96 (91.3–100)

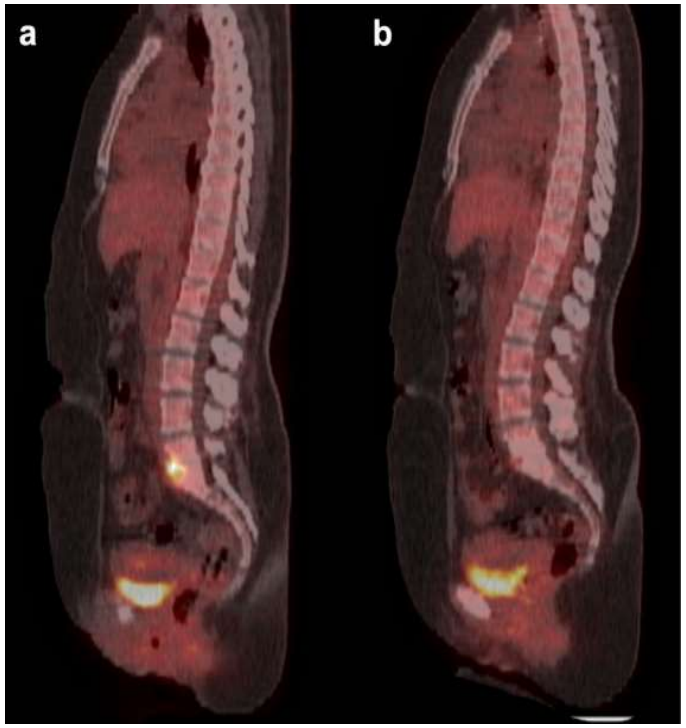

SPECT-CT → verhoogde accuraatheid en diagnostische zekerheid

- Stressreacties / -fractuurhaarden
- Posttraumatische letsels
- Arthrose / Arthritis
- Facet / Discus / SI-lijden
- Evaluatie indeukingsfracturen
- Insufficiëntiefracturen
- Pijn na rugchirurgie
- Polyarticulaire klachten / Malpartout
- Costochondritis / Tietze
- Pijn na prothesechirurgie
- Pijn na arthrodesechirurgie
- CRPS / Sudeck
- Gerefereerde pijnsyndromen
- Botmetastasering / maligne botinvasie
- Osteomyelitis / spondylodiscitis
- AVN
- Metabole botaandoeningen
- Ziekte van Paget

MARIA MIDDELARES

Praktisch

- Botscan:
  - Eerst inspuiting, enkele uren nadien terugkomen voor scan (tijdstip van scan wordt meegegeven bij inspuiting).
  - Voldoende drinken.

MARIA MIDDELARES

Praktisch

- Botscan:

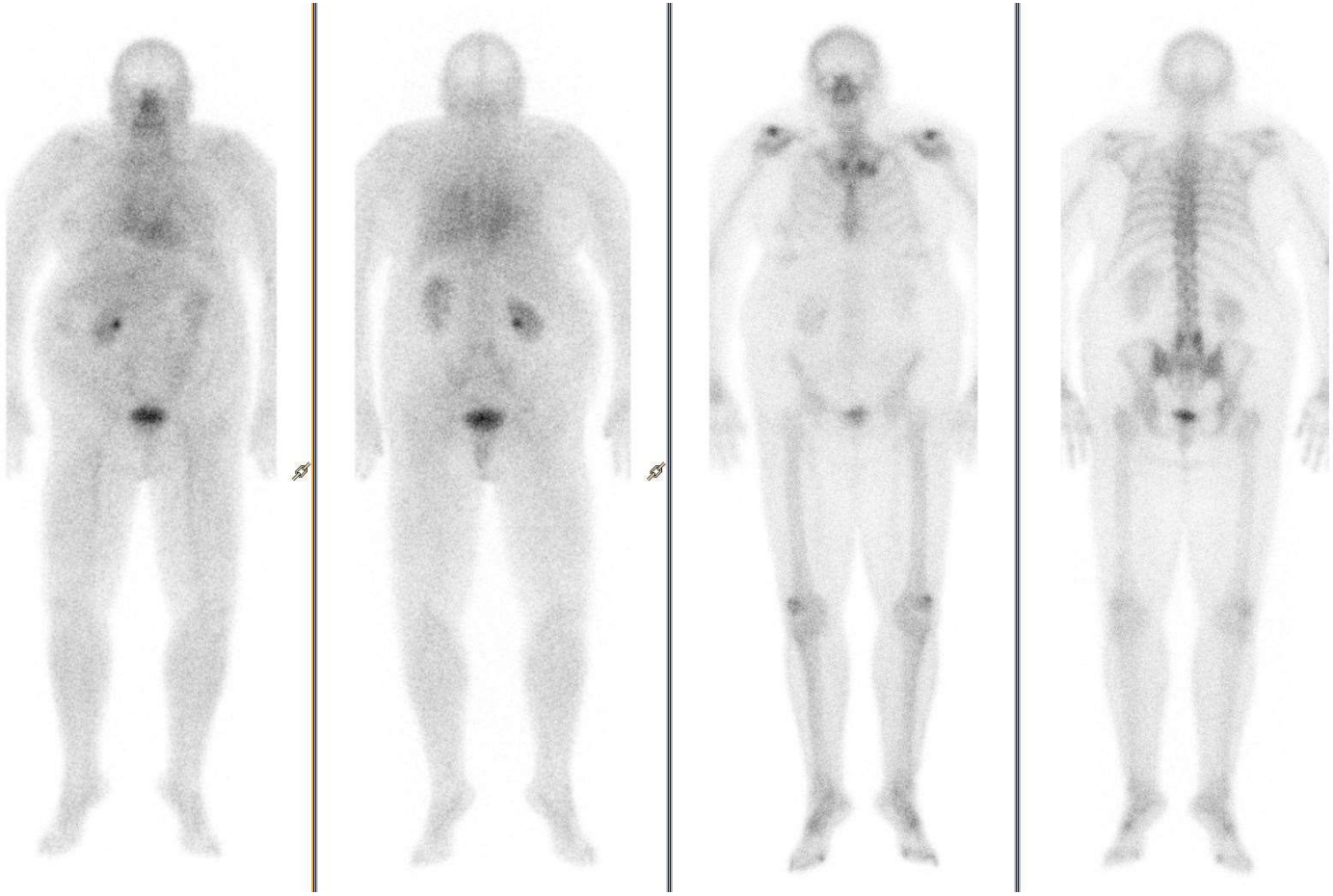

MARIA MIDDELARES

Praktisch

- Botscan:
  - Eerst inspuiting, enkele uren nadien terugkomen voor scan (tijdstip van scan wordt meegegeven bij inspuiting).
  - Voldoende drinken.
- Leukocytenscan
  - Eerst bloedafname, labelen WBC, na enkele uren inspuiting.
  - Scans na 1u., 4u. en 24u. na de inspuiting.

MARIA MIDDELARES

Dienst Nucleaire Geneeskunde

09 246 96 00

MARIA MIDDELARES

GezondheidsZorg met een Ziel