Inwendige Nucleaire Functionele Beeldvorming

Dr. Dieter Berwouts

Medische kring 29/01/2019

MARIA MIDDELARES

GezondheidsZorg met een Ziel

NUCLEAIRE GENEESKUNDE
AZ Maria Middelares
Buitenring Sint-Denijs 30
9000 Gent
tel: 09 246 96 00

MARIA MIDDELARES

Dr. Bieke Van Den Bossche
Prof. Dr. Bieke Lambert
Dr. Jeroen Mertens
Dr. Dieter Berwouts

Identificatie van de patiënt — Kamer:
Naam: ..... Voornaam: .....
geb. datum: .....
kleefvignet

Aanvrager:

datum, stempel en handtekening

Kopie naar:

Vink aan indien van toepassing:

- o Zwangerschap / Borstvoeding
- o Isolatie patiënt
- o Allergie:
- o Besmettingsgevaar:
- o Andere opmerking:

Vorige relevante RX onderzoeken:

- o CT:
- o MRI:
- o Echo:
- o Andere:

Diagnostische vraagstelling:

Relevante klinische inlichtingen:

AANVRAAG VOOR ISOTOPENONDERZOEK
voorgesteld onderzoek:

AANVRAAG VOOR SPECT-CT
voorgesteld onderzoek / richtlijnen

SKELET
- o Skeletscintigrafie
- o Vasculaire scan
- o WBC - Granulocyten

ENDOCRINOLOGIE
- o Schildklier
- o Bijschildklier
- o Bijnier (merg/cortex)

HERSENEN
- o Perfusie NeuroSPECT
- o DAT-scan
- o PET (zie ommezijde)

VARIA
- o Gastric banding
- o Lymfescan BL/OL
- o Speekselklierscan
- o Inflammatie/infectie
- o *Andere:*

ONCOLOGIE
- o Sentinelklier
- o Porth-a-cath
- o MIBG
- o I123-scan totaal lichaam
- o PET-scan (zie ommezijde)
- o *Andere:*

NIEREN
- o Morfologie / splitfunctie (DMSA)
- o Renogram (+ Lasix)
  - o Captopril test
- o GFR met Cr51-EDTA

MAAG-DARM-LEVER
- o Maagevacuatie (nuchter!)
- o GO reflux (nuchter!)
- o Leverfunctie / galwegen (HIDA)
- o Opsporen Meckel / GI-bloeding
- o *Andere:*

NUCLEAIRE THERAPIE
- o I-131 hyperthyroïdie
- o I-131 schildkliercarcinoom
- o Xofigo (Ra-223)
- o Quadramet (Sm-153)
- o SIRT lever (Y90-sfeertjes)
- o radiosynovectomie
- o *Andere:*

HART - LONGEN
- o Ventrikelfunctie (EF)
  - o LV (planair / MIBI)
  - o RV+LV (GBS)
- o Myocardperfusie (MIBI) (nuchter!)
  - o Stress °fietsproef
    °Persantine (LBBB!)
  - o Rust
- o Rechts-links shunt
- o V/Q scan
  - o % verdeling

Informatiebrochures via http://www.mariamiddelares.be/nl/medisch-aanbod/specialismen/artsen/nucleaire-geneeskunde

SKELET
- ☐ Skeletscintigrafie
- ☐ Vasculaire scan
- ☐ WBC - Granulocyten

ENDOCRINOLOGIE
- ☐ Schildklier
- ☐ Bijschildklier
- ☐ Bijnier (merg/cortex)

HERSENEN
- ☐ Perfusie NeuroSPECT
- ☐ DAT-scan
- ☐ PET (cfr aparte aanvraag)

VARIA
- ☐ Gastric banding
- ☐ Lymfescan BL/OL
- ☐ Speekselklierscan
- ☐ Inflammatie/infectie
- ☐ Andere:

ONCOLOGIE
- ☐ Sentinelklier
- ☐ Porth-a-cath
- ☐ MIBG
- ☐ I123-scan totaal lichaam
- ☐ PET-scan (cfr aparte aanvraag)
- ☐ Andere:

NIEREN
- ☐ Morfologie / splitfunctie (DMSA)
- ☐ Renogram (+ Lasix)
  - ☐ Captopril test
- ☐ GFR met Cr51-EDTA

MAAG-DARM-LEVER
- ☐ Maagevacuatie (nuchter!)
- ☐ GO reflux (nuchter!)
- ☐ Leverfunctie / galwegen (HIDA)
- ☐ Opsporen Meckel / GI-bloeding
- ☐ Andere:

NUCLEAIRE THERAPIE
- ☐ I-131 hyperthyroïdie
- ☐ I-131 schildkliercarcinoom
- ☐ Xofigo (Ra-223)
- ☐ Quadramet (Sm-153)
- ☐ SIRT lever (Y90-sfeertjes)
- ☐ Radiosynovectomie
- ☐ Andere:

HART - LONGEN
- ☐ Ventrikelfunctie (EF)
  - ☐ LV (planair / MIBI)
  - ☐ RV+LV (GBS)
- ☐ Myocardperfusie (MIBI) (nuchter!)
  - ☐ Stress °fietsproef
    °Persantine (LBBB!)
  - ☐ Rust
- ☐ Rechts-links shunt
- ☐ V/Q scan
  - ☐ % verdeling

MARIA MIDDELARES

Nieren - Functionele analyse

NIEREN

☐ Morfologie / splitfunctie (DMSA)

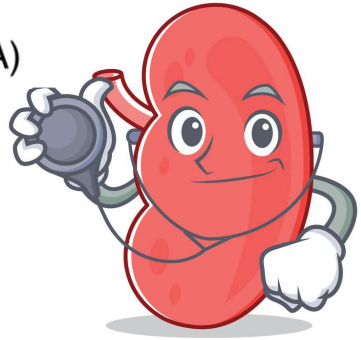

^{99m}Tc-DMSA: dimercaptosuccynil acid

Marker voor tubulaire filtratie

Indicaties:

- Morfologie – post-pyelonefritis
- pre-operatieve analyse en kwantificatie
- Congenitale afwijkingen
- Opnames na 4 uur (morfologie) en 24 uur (kwantificatie)

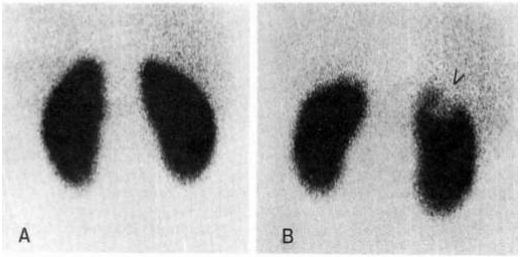

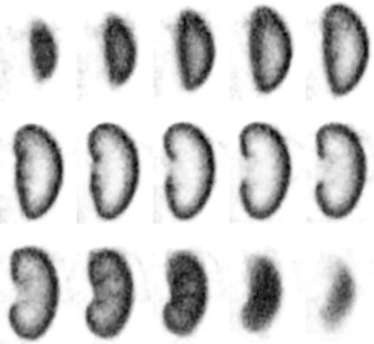

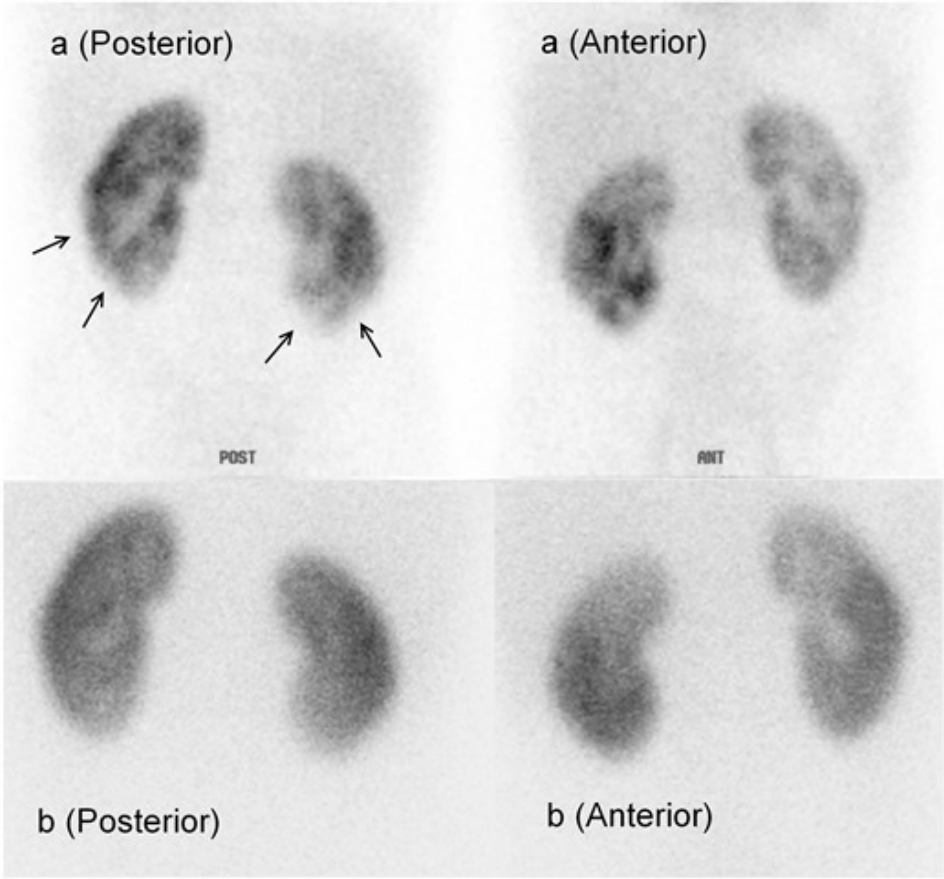

MARIA MIDDELARES

Hitzel A, 2014
Kjim.org

Nieren - Afloopevaluatie

☐ Renogram (+ Lasix)
☐ Captopril test

Tc-99m MAG3 of DTPA

>95% tubulaire secretie MAG3

>95% glomerulaire filtratie DTPA

Indicaties:
- Perfusie analyse
- (congenitale) afvloeistoornissen

- Combineerbaar met Lasix (na 20 min)

- Combineerbaar met captopril evaluatie a. renalis stenose

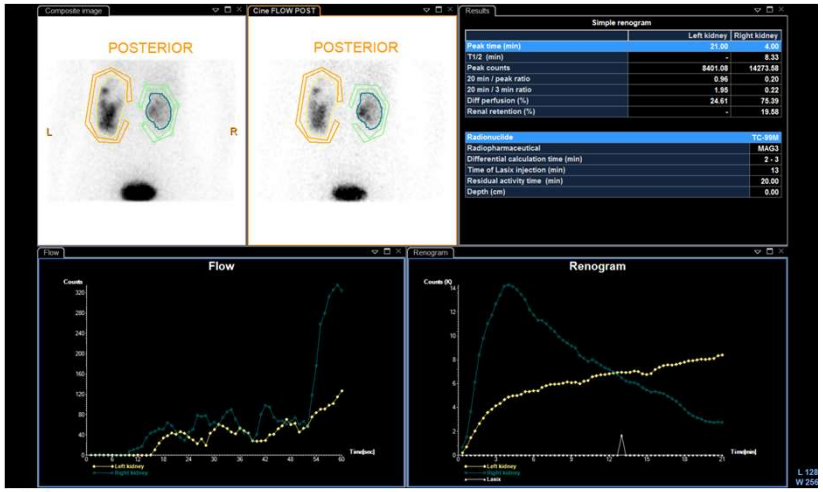

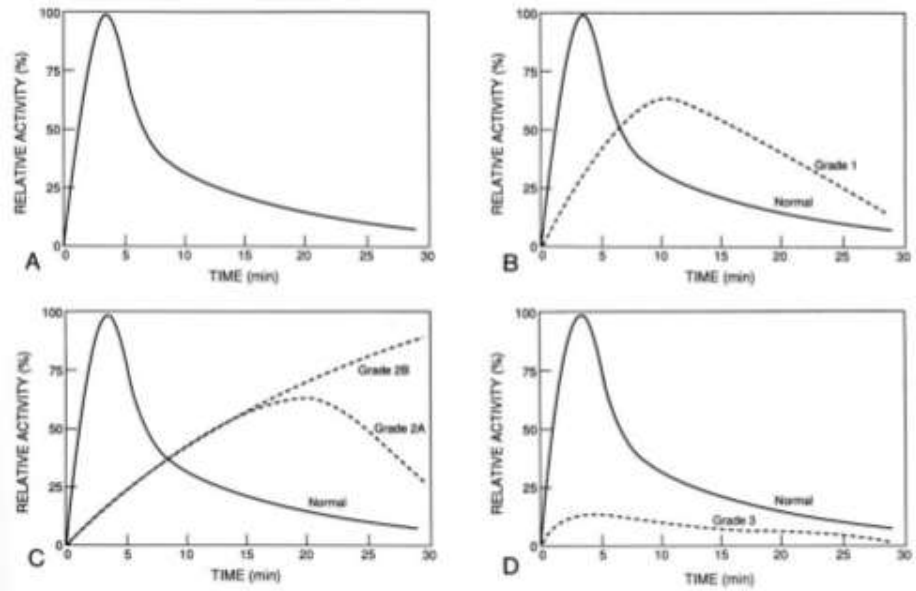

MARIA MIDDELARES

Kidney international.org

Nieren – GFR-bepaling

☐ GFR met Cr51-EDTA

^{51}CR-EDTA: gouden standaard ter bepaling van de nierfunctie

Half-leven ($T^{1/2}$): 27,7 dagen.
2.0 MBq IV.

- Glomerulaire filtratie rate (GFR) gebruikt als standaard ter bepaling van nierfunctie.

- Berekend als AUC bij multipele metingen van bloed (na 2, 3 en 4 uur)

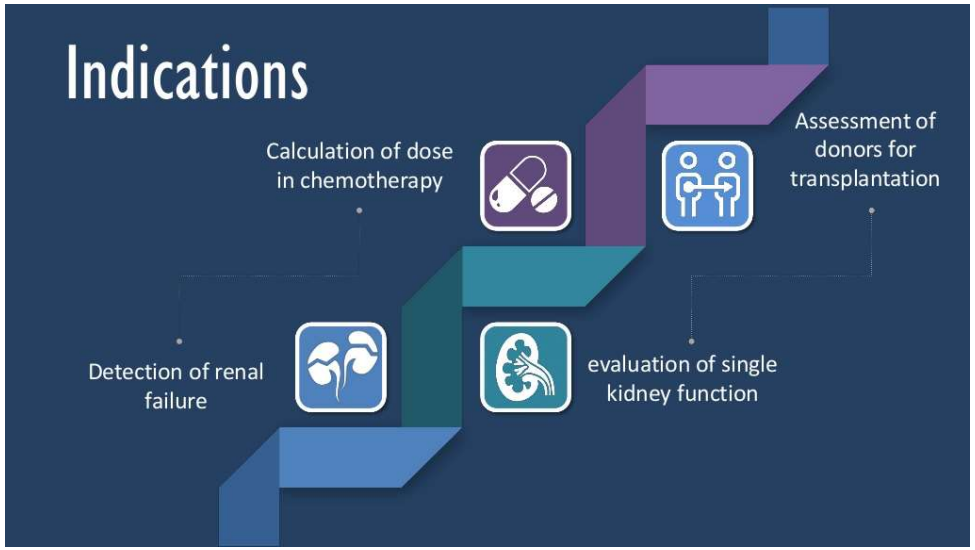

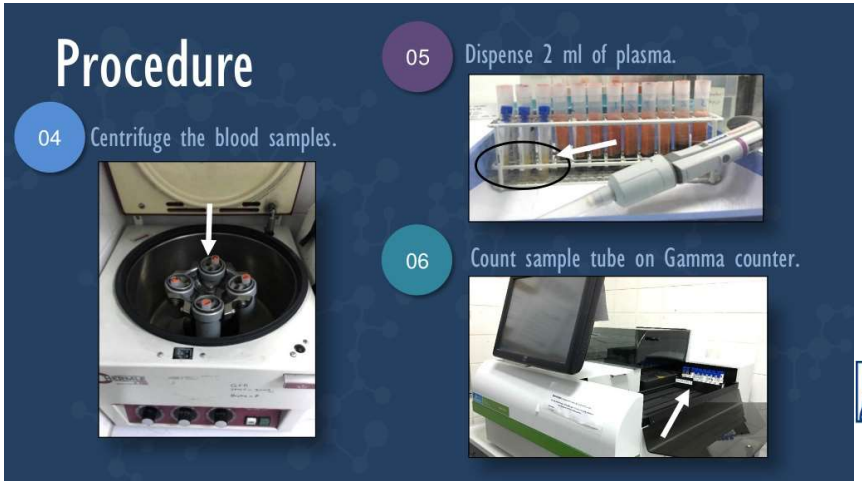

MARIA MIDDELARES

Gastro-intestinaal - Maaglediging

MAAG-DARM-LEVER

☐ Maagevacuatie (nuchter!)

INDICATIES:

Verdenking op maagontledigingsstoornissen (vertraagd, versneld of veranderd patroon), zoals bij :

- **neurogene pathologie:** sclerodermie, diabetes mellitus of amyloidose

- **bovenbuiksklachten** (na heelkunde / medicatie)

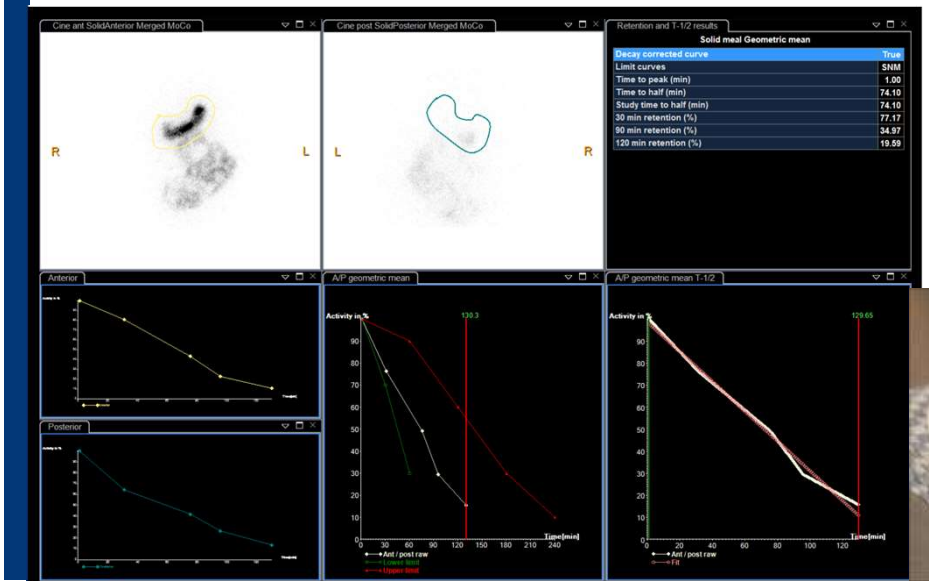

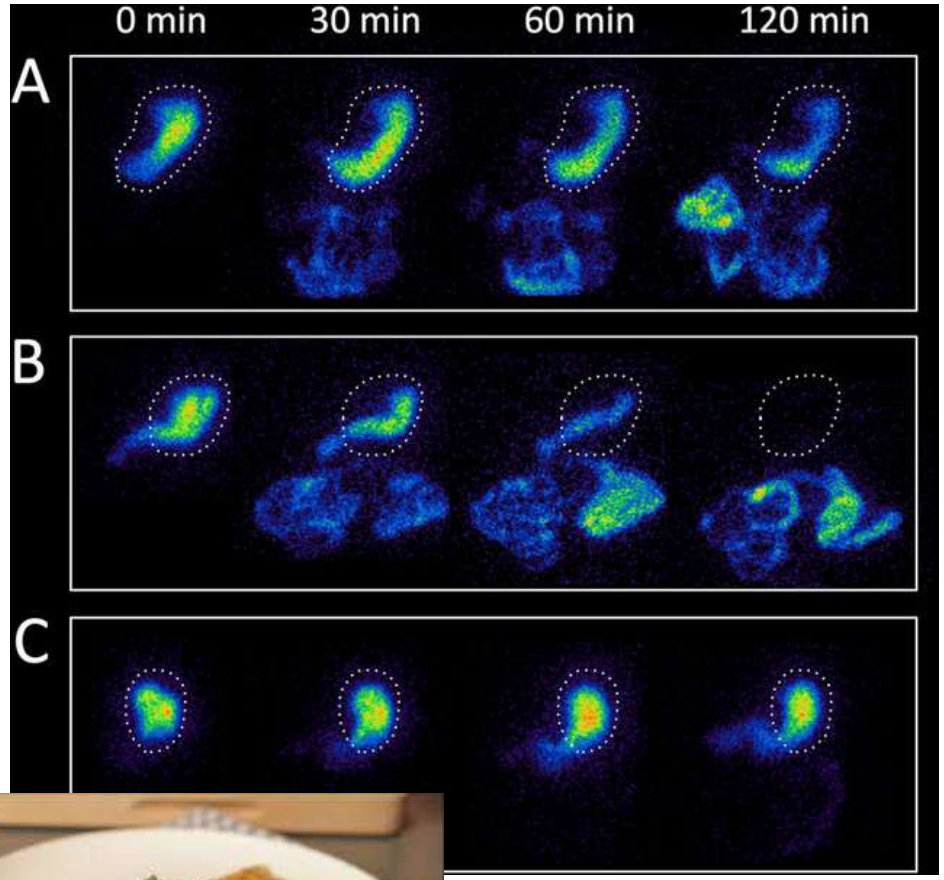

MARIA MIDDELARES

Borghammer P, 2018

Gastro-intestinaal – Opsporen Divertikel van Meckel

- Opsporen Meckel / GI-bloeding

Divertikel van Meckel:
congenitaal ectopisch maagslijmvlies.

^{99m}TC Pertechnetaat ("vrij technetium").

Indicaties:
Acuut of occult bloedverlies per anum

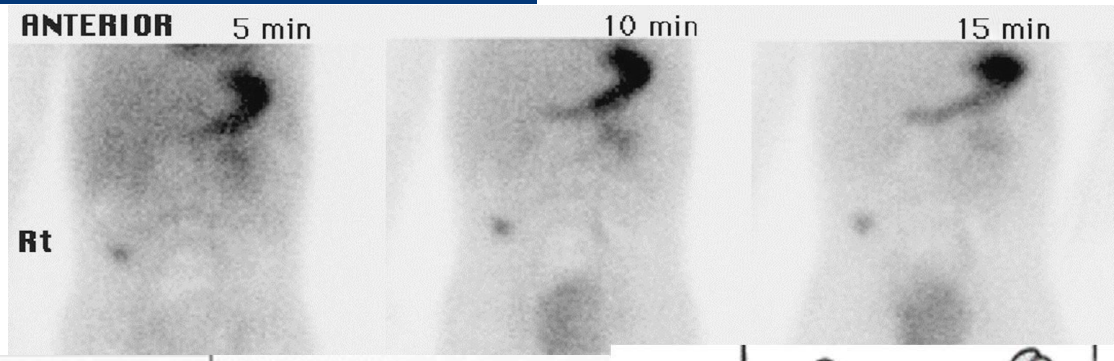

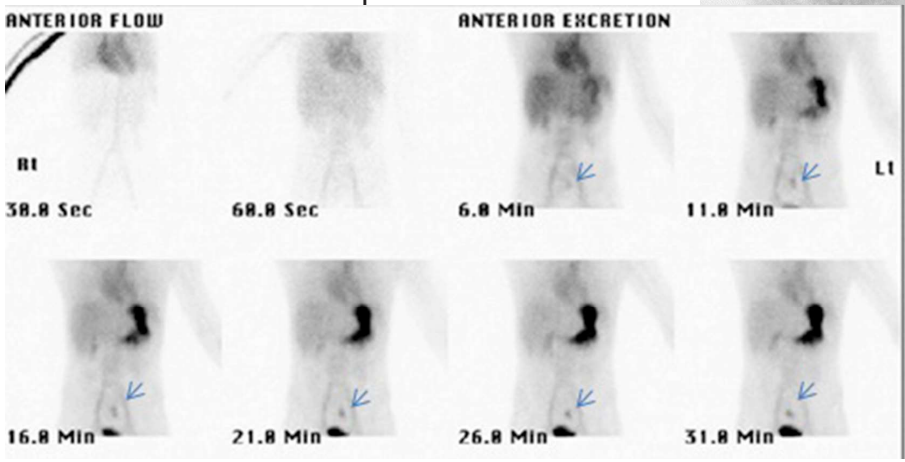

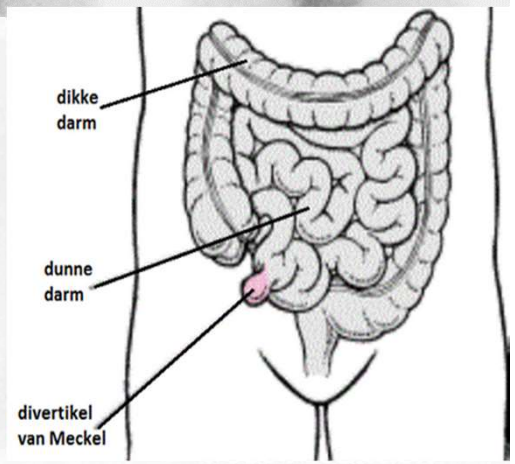

MARIA MIDDELARES

Dames EL, 2015
Msdmanuals.nl

Leverfunctie-testen - HIDA

☐ Leverfunctie / galwegen (HIDA)

INDICATIES:

- Pre leverheelkunde
- Biliaire reflux na bypasschirurgie
- Gallek na heelkunde

- Nuchter: 4 uur voor onderzoek.

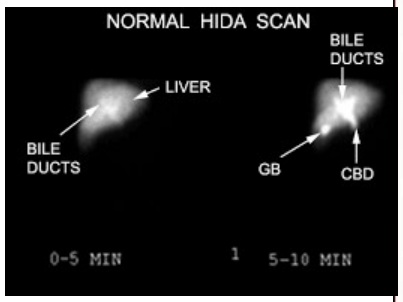

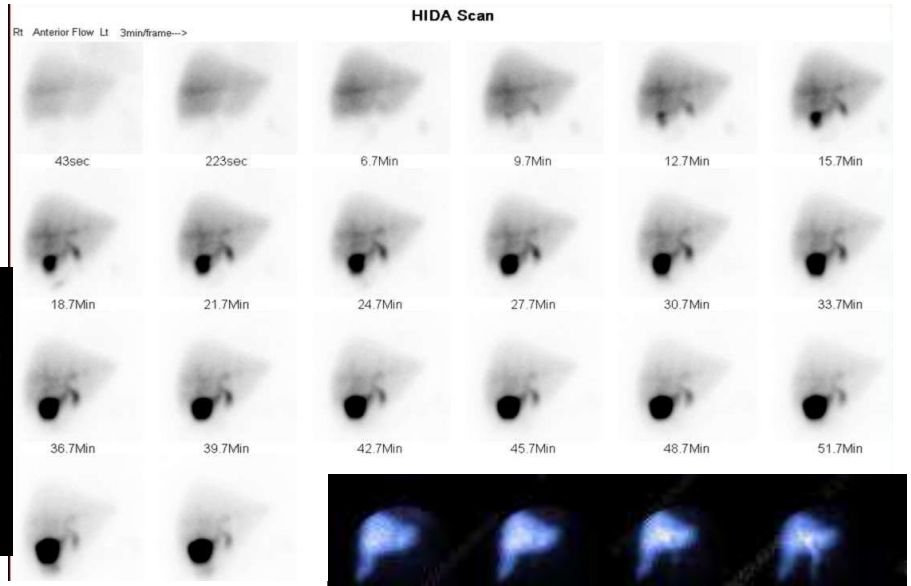

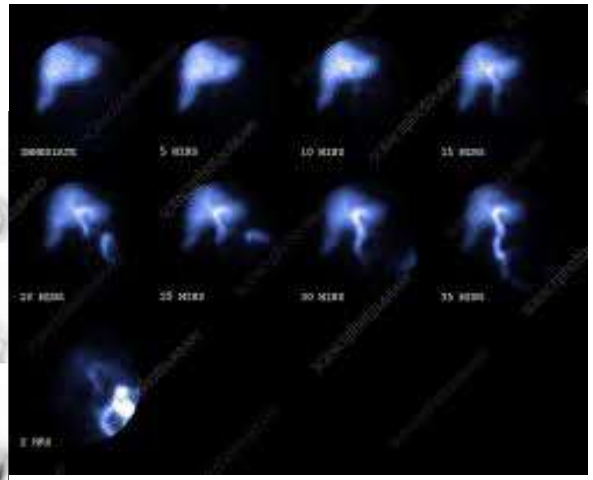

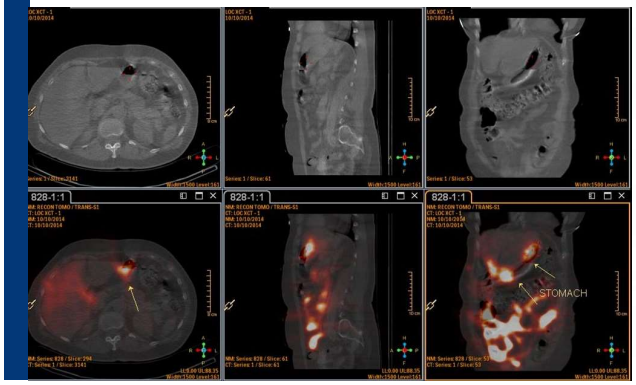

MARIA MIDDELARES

stritch.luc.edu

Longscintigrafie

- ☐ Rechts-links shunt
- ☐ V/Q scan
  - ☐ % verdeling

INDICATIES:

- Vaststellen acute longembolie
- Echter ook opvolging (resolutie?) chronische LE
- Quantificatie pre-heelkunde
- Evaluatie functie longtransplant
- Shunting
- oorzaak pulmonale hypertensie!

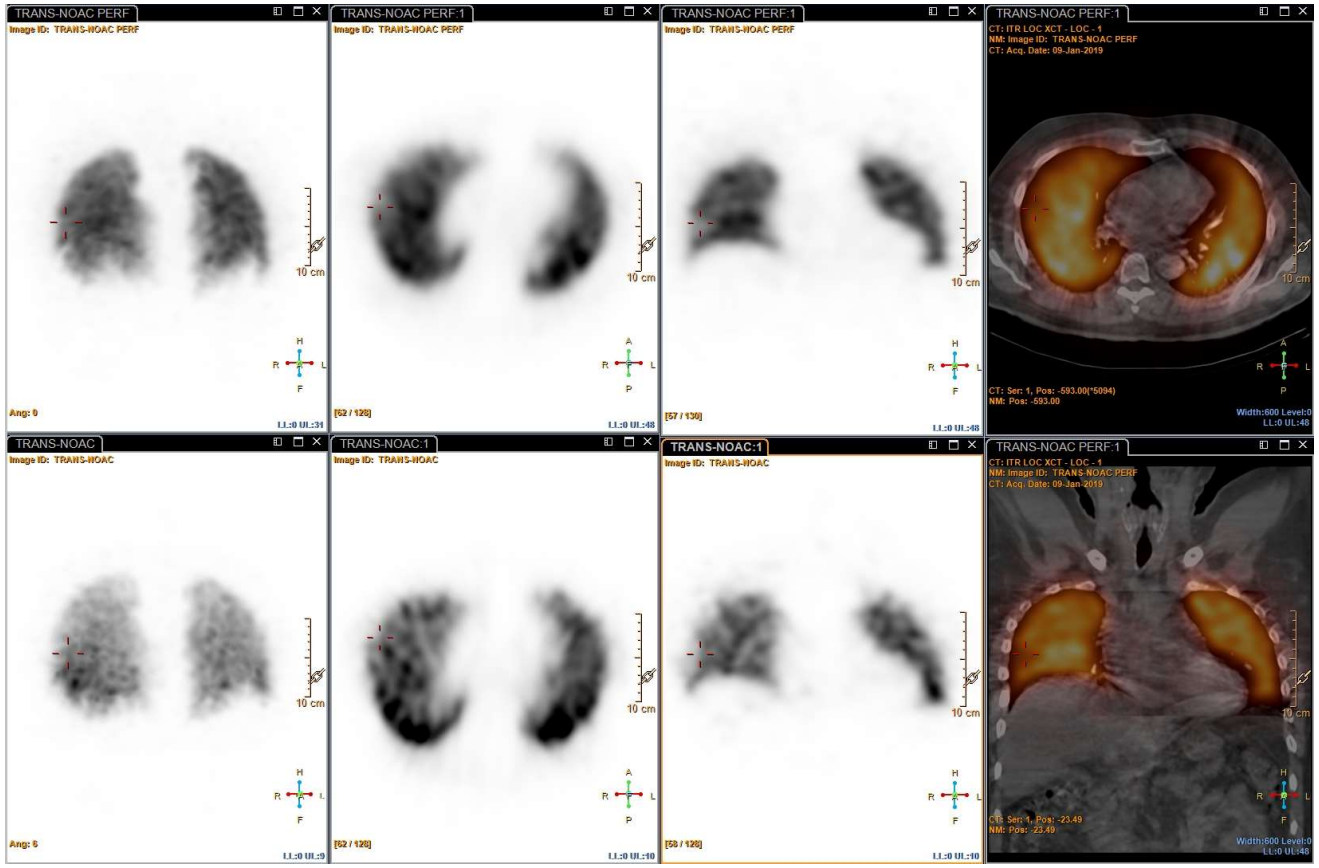

MARIA MIDDELARES

Longscintigrafie – PAH vs CTEPH

Sensitiviteit > 96%.

Normale V/Q-scintigrafie kan CTEPH uitsluiten.

Zelfs indien CT negatief, is een positieve V/Q-scintigrafie in suggestief voor CTEP.

Lage dosis (1-2 mSv).

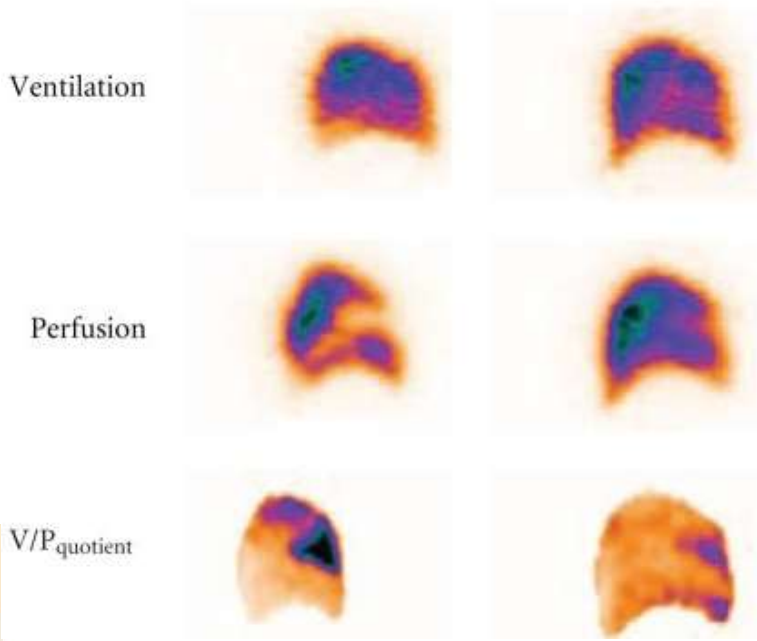

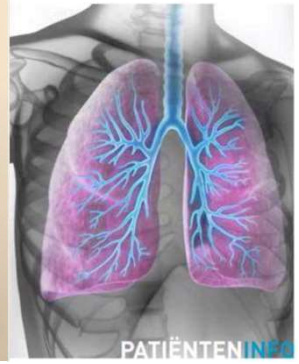

MARIA MIDDELARES

Bajc, M, 2011

When to use CTA or V/Q scanning

Clinicians need to consider:

- Institution's experience, particularly for CTA, variable predictive values
- Pretest probability of PE (Wells likely)
- Age and gender of the patient
- Renal failure
- Contrast media allergy

CTA preferred:

- Experienced CTA reading
- High clinical suspicion for PE
- Clinical suspicion for parenchy

V/Q as alternative:

- Inexperienced CTA reading
- Inconclusive CTA but high clinical suspicion for PE
- Contraindications for CTA (renal failure, contrast allergy)
- To minimize radiation dose to patient, particularly in women of young age

XR

When to use CTA or V/Q scanning?

Radiation Exposure

Exposure	Effective Whole-Body Dose (mSv)	References
Posteroanterior and lateral chest radiography	0.07	11
Perfusion scan	0.8	7
Ventilation-perfusion scan	1.2–2.0	7, 10
Contrast-enhanced multidetector CT angiography	1.6–8.3	6–10
Contrast-enhanced multidetector CT venography	5.7	10
Pulmonary digital subtraction angiogram	3.2–30.1	6–10
Background radiation per year	2.5	5
Maximum allowable exposure per year for radiation workers	50	12
Average allowable exposure per year for radiation workers	20	12
Contrast CT of chest	5-8	

MARIA MIDDELARES

Longscintigrafie

- ☐ Rechts-links shunt
- ☐ V/Q scan
  - ☐ % verdeling

INDICATIES:

- Quantificatie pre-heelkunde.
- Evaluatie functie longtransplant.
- Shunting.
- oorzaak pulmonale hypertensie!

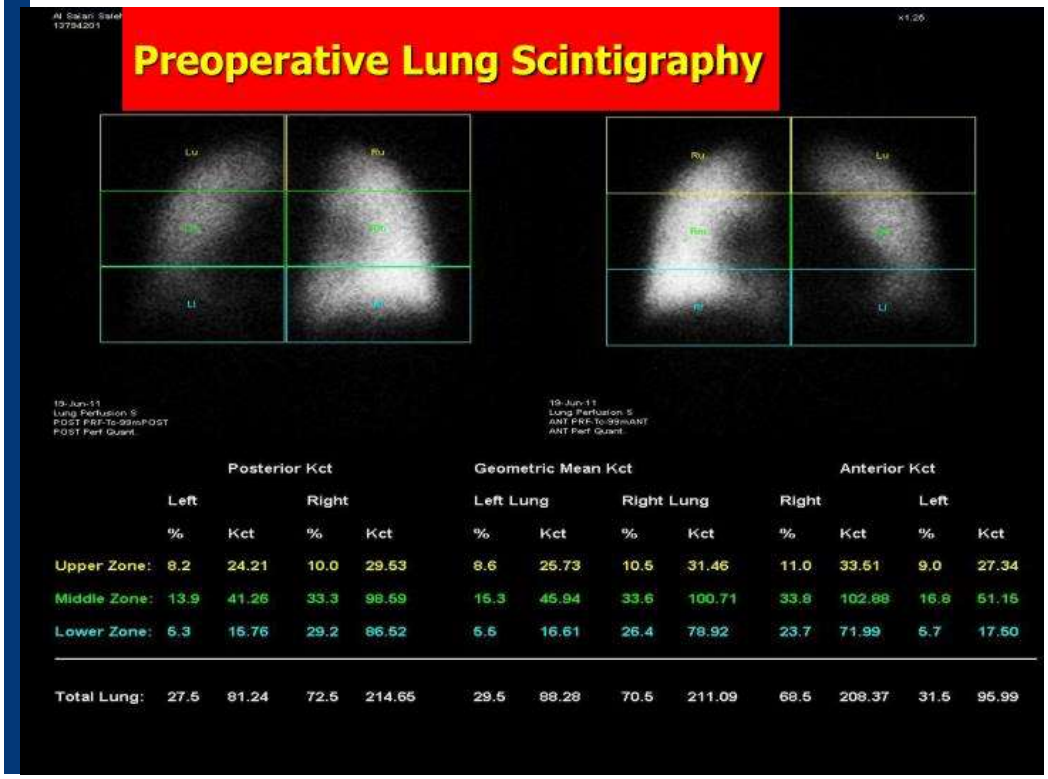

	Posterior Kct				Geometric Mean Kct				Anterior Kct			
	Left		Right		Left Lung		Right Lung		Right		Left	
	%	Kct	%	Kct	%	Kct	%	Kct	%	Kct	%	Kct
Upper Zone:	8.2	24.21	10.0	29.53	8.6	25.73	10.5	31.46	11.0	33.51	9.0	27.34
Middle Zone:	13.9	41.26	33.3	98.59	15.3	45.94	33.6	100.71	33.8	102.88	16.8	51.15
Lower Zone:	6.3	15.76	29.2	86.52	5.6	16.61	26.4	78.92	23.7	71.99	5.7	17.50
Total Lung:	27.5	81.24	72.5	214.65	29.5	88.28	70.5	211.09	68.5	208.37	31.5	95.99

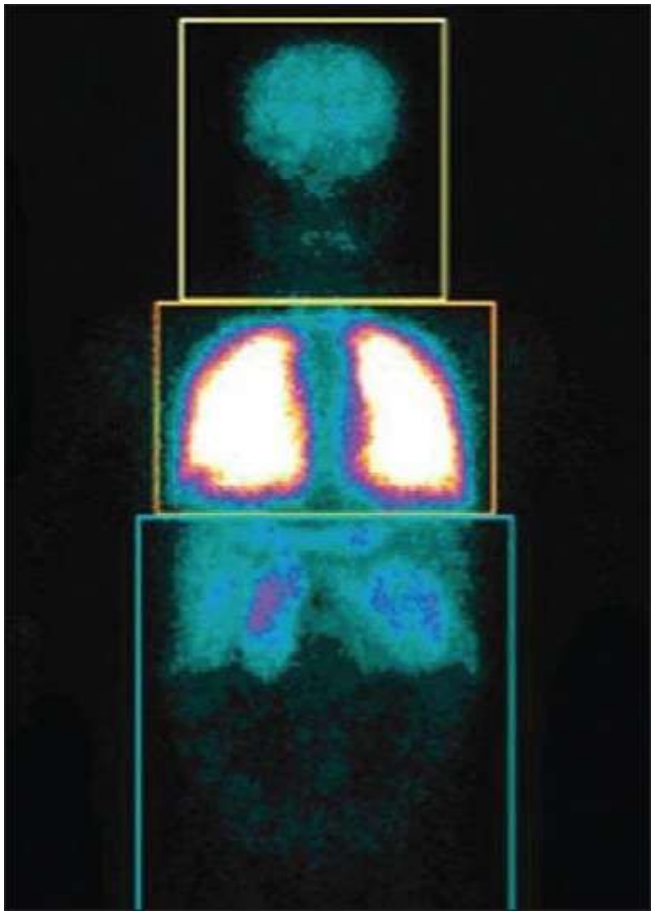

MARIA MIDDELARES

Gandhi S, 2013

Speekselklierscintigrafie

☐ Speekselklierscan

Indicaties:
- Sjögren (gradatie)
- Medicamenteus geinduceerde xerostomie
- Post-radio/chemotherapie
- Postinfectieus

Dynamisch onderzoek

Citroensap na 20 minuten

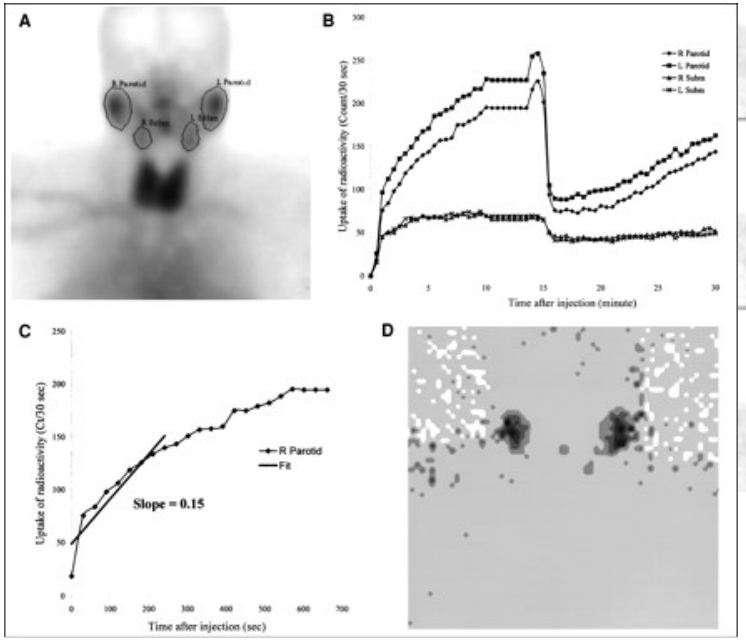

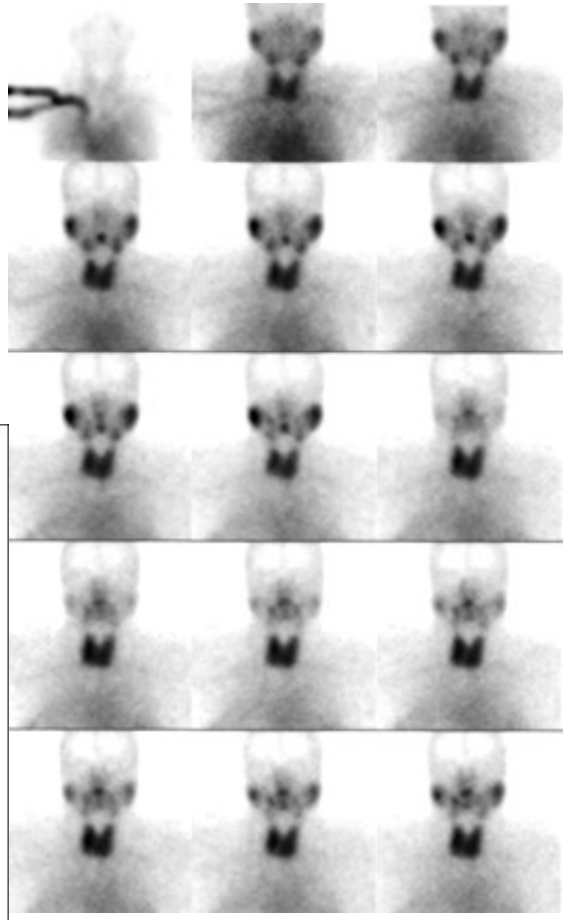

MARIA MIDDELARES

Loufti et al 2003
Kisspng.com

Lymfescintigrafie

☐ Lymfescan BL/OL

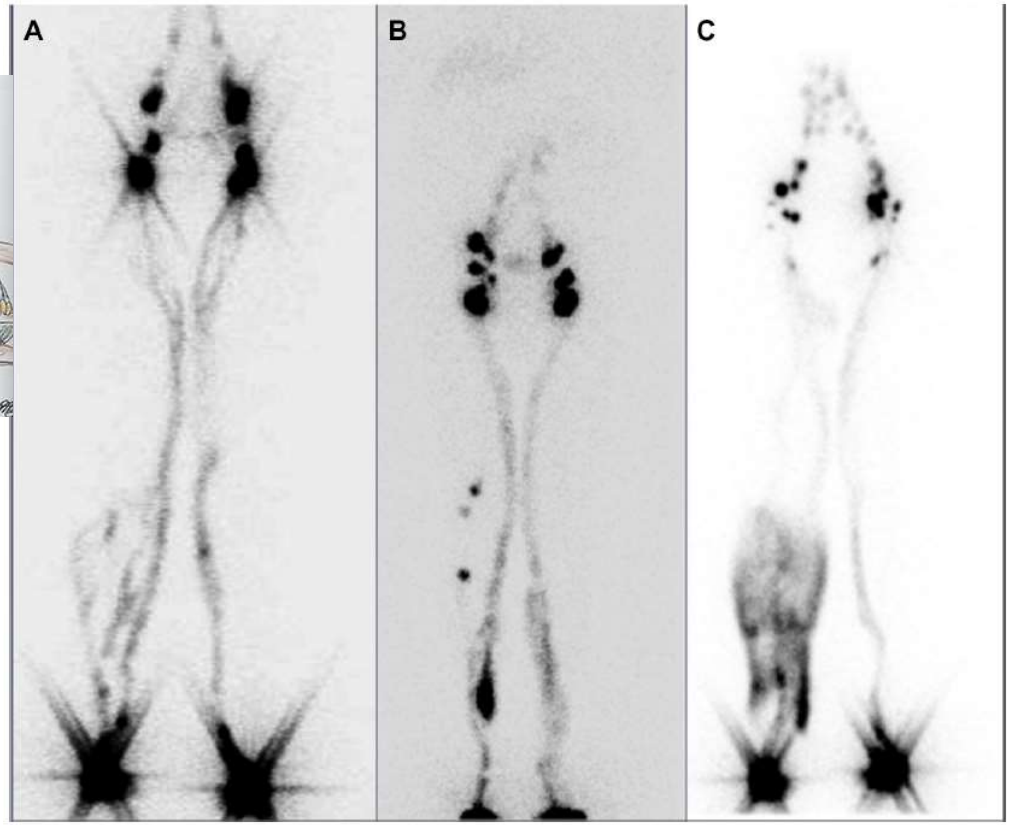

INDICATIES:

- Diagnose lymfeafvloeiproblemen
  - primair
  - secundair (na heelkunde)
- pre-operatieve evaluatie
- Terugbetaling lymfedrainage

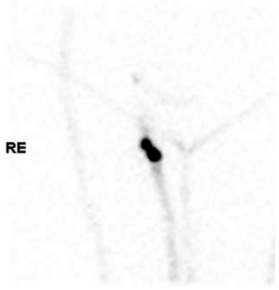

ANTERIOR BEKKEN NA 30

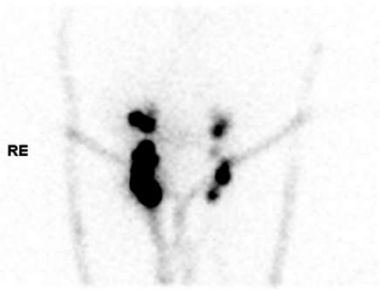

ANTERIOR BEKKEN NA 2 UUR

MARIA MIDDELARES

Vidal-Sicart S, 2015
lymphnodetransplant.wordpress.com

Lymfescintigrafie

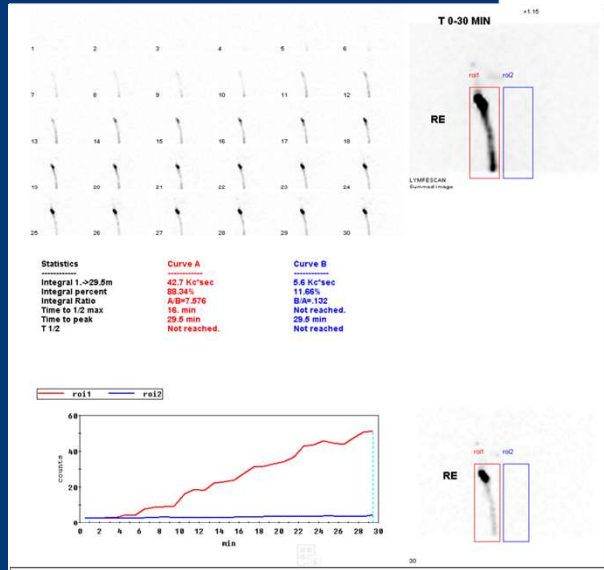

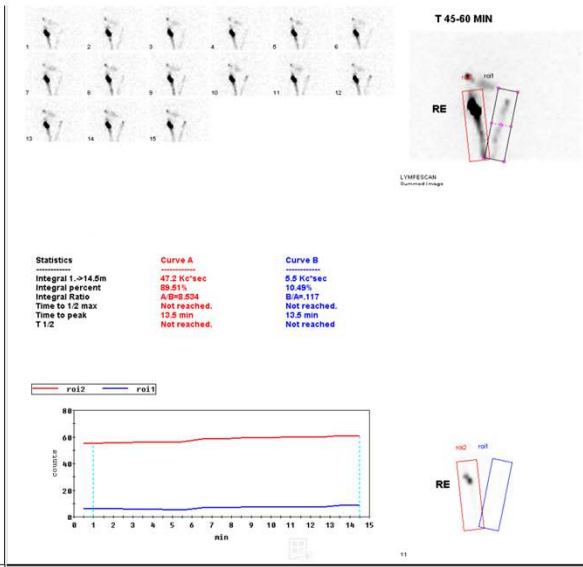

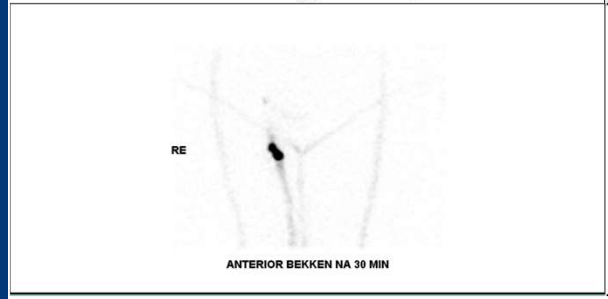

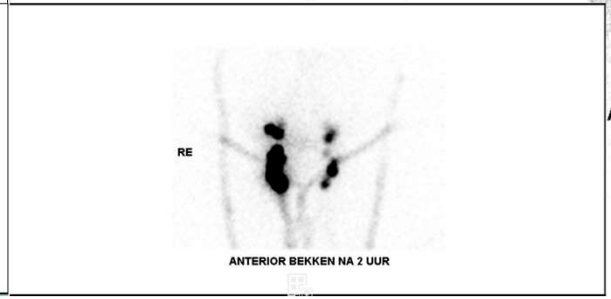

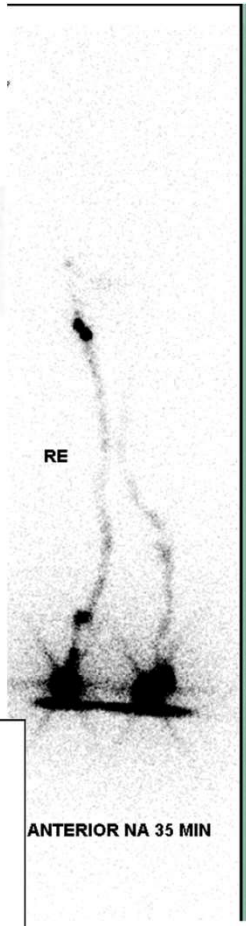

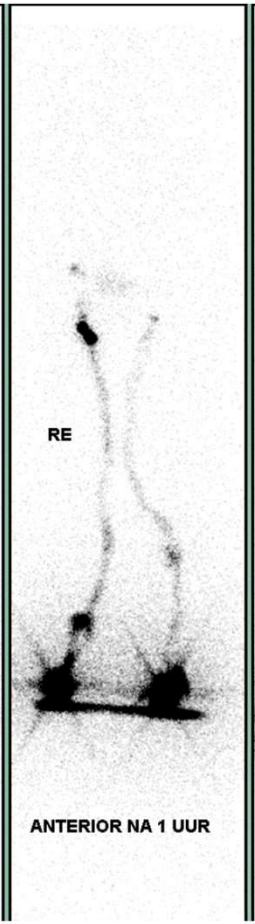

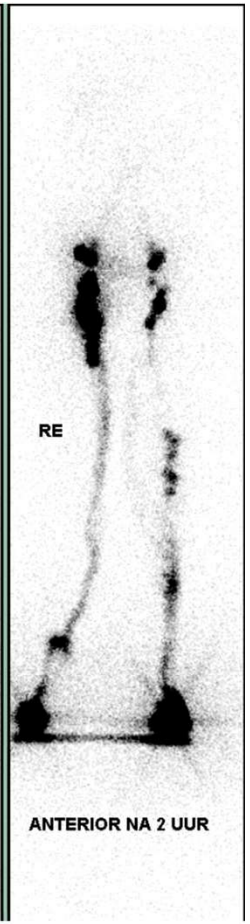

MARIA MIDDELARES

Cardiologie

☐ Myocardperfusie (MIBI) (nuchter!)
- ☐ Stress °fietsproef
  °Persantine (LBBB!)
- ☐ Rust

^{99m}TC-MIBI

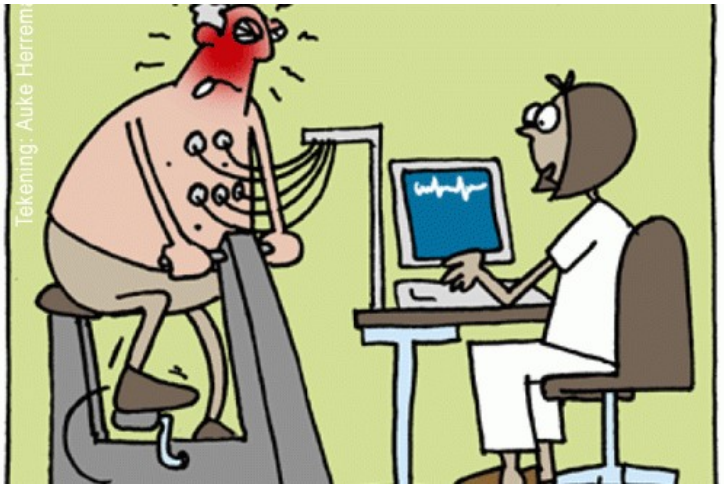

Indicaties:

Aantonen of uitsluiten van ischemisch hartlijden; meer specifiek:

- Middel tot hoog risicopatiënten.
- Uitgebreidheid en ernst
- Functionele parameters

Voorbereiding RUST:

- nuchter, geen koffie, geen thee
- medicatie kan met beperkte hoeveelheid water

Voorbereiding STRESS

- Licht ontbijt, geen koffie, geen thee
- 24u op voorhand te stoppen: nitraten, beta-blokker en Ca-antagonisten.

- Gebruik van *persantine - adenosine - dobutamine*
- Fietstest onder supervisie cardioloog
- Minimaal 85% maximaal verwachte hartslag voor correct onderzoek!

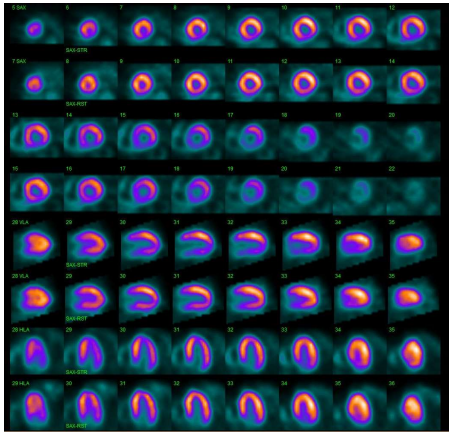

MARIA MIDDELARES

Medicalexpo.com
Cartoonstock.com

MIBI Stress Rust

STRESS →

RUST →

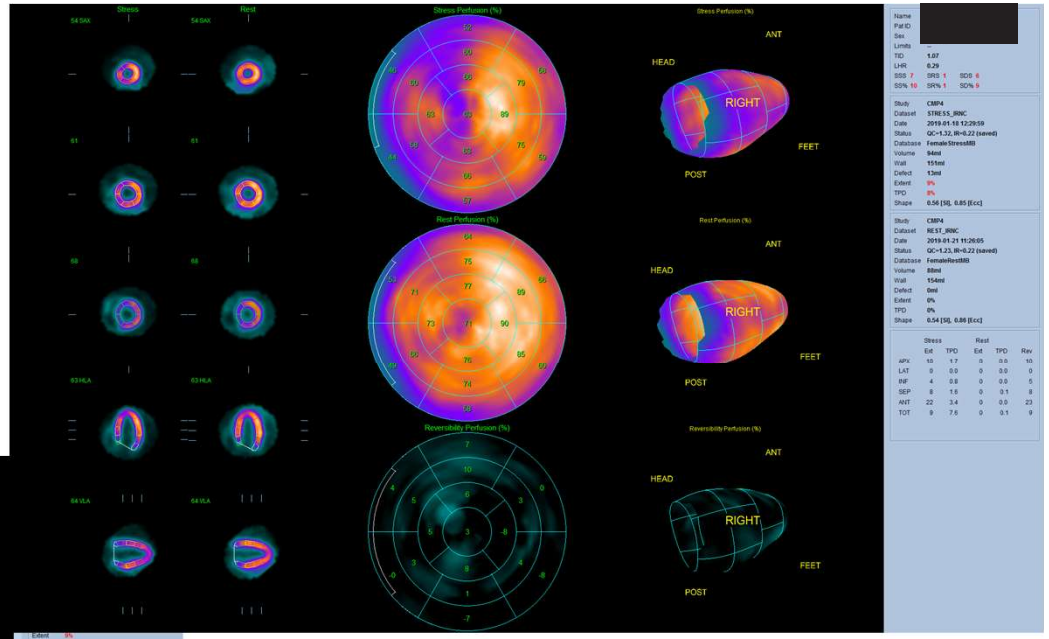

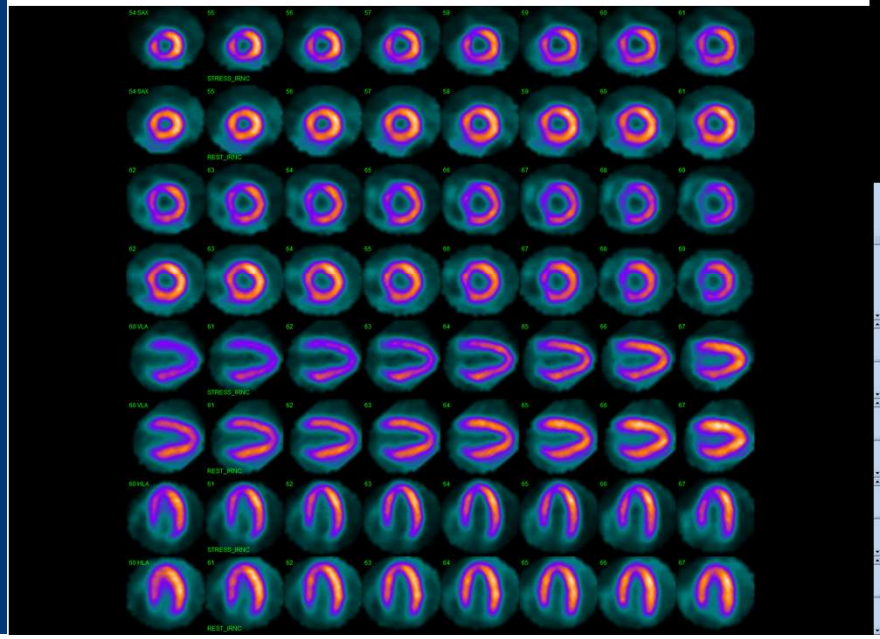

MARIA MIDDELARES

LV-ejectiefractie

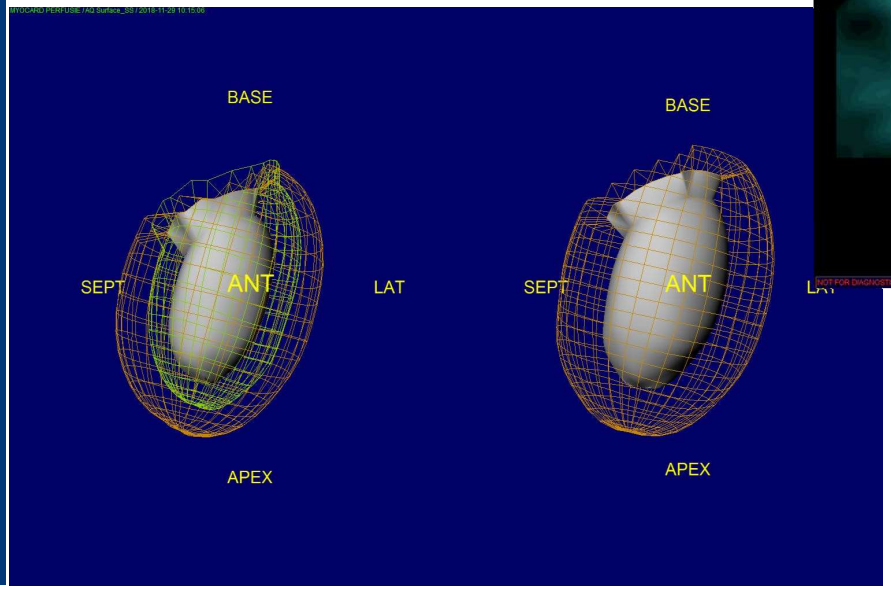

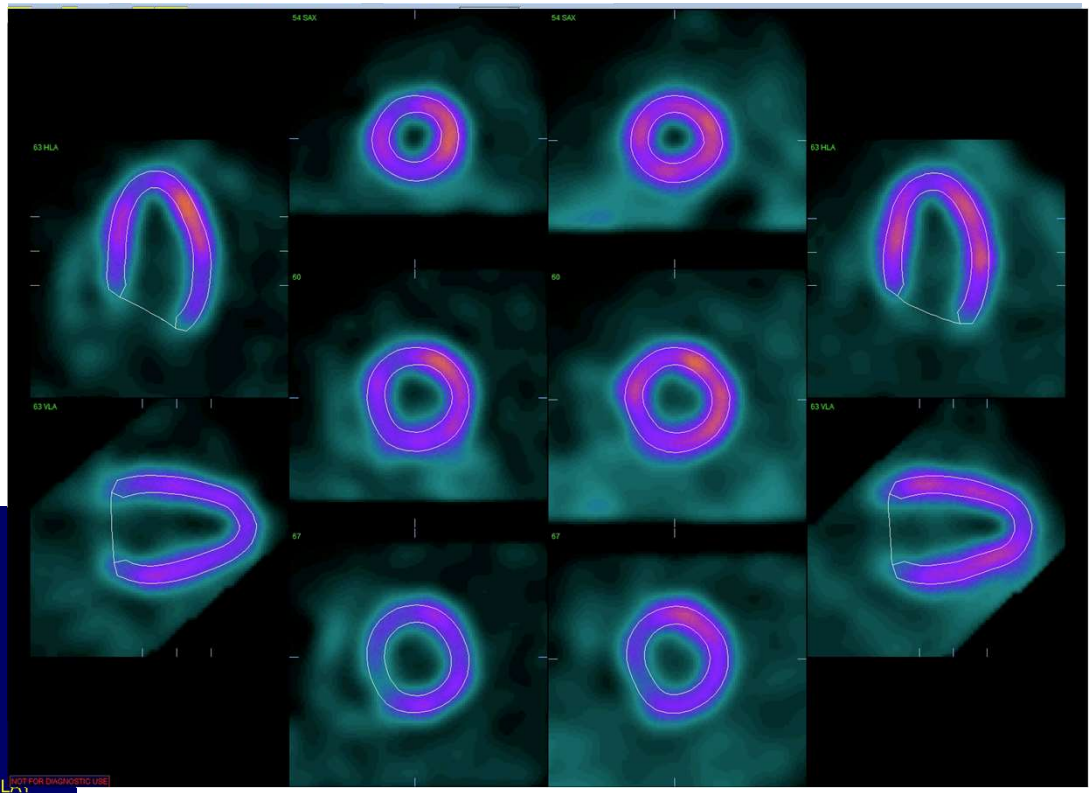

STRESS

RUST

MARIA MIDDELARES

Coronaro-SPECT/CT

Stress-opnames

Rust-opnames

Substractie

MARIA MIDDELARES

Pilootproject in Belgie i.s.m. Dienst radiologie en cardiologie

Dyssynchronie

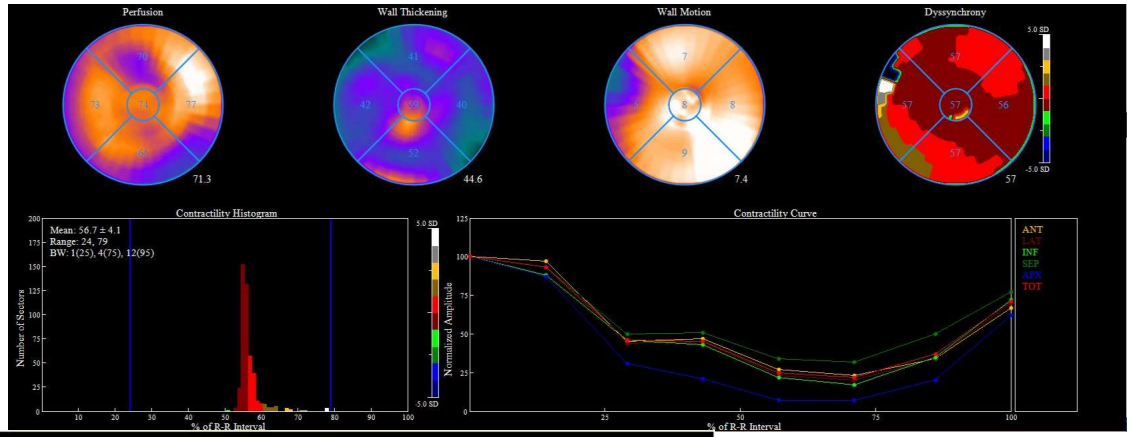

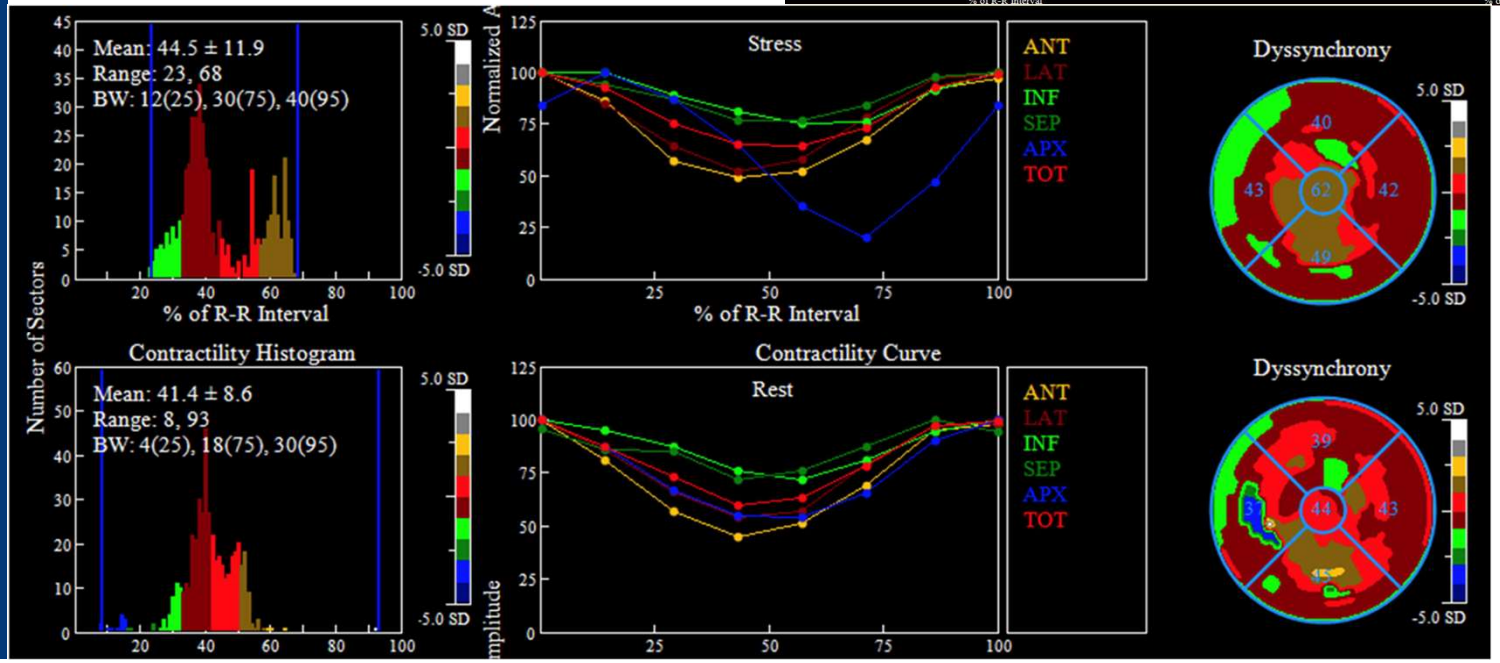

- Bij LBTB: tot 70%
- Slechtere prognose
- Reconversie
- Viabiliteit laterale wand

MARIA MIDDELARES

Viabiliteit – FDG PET

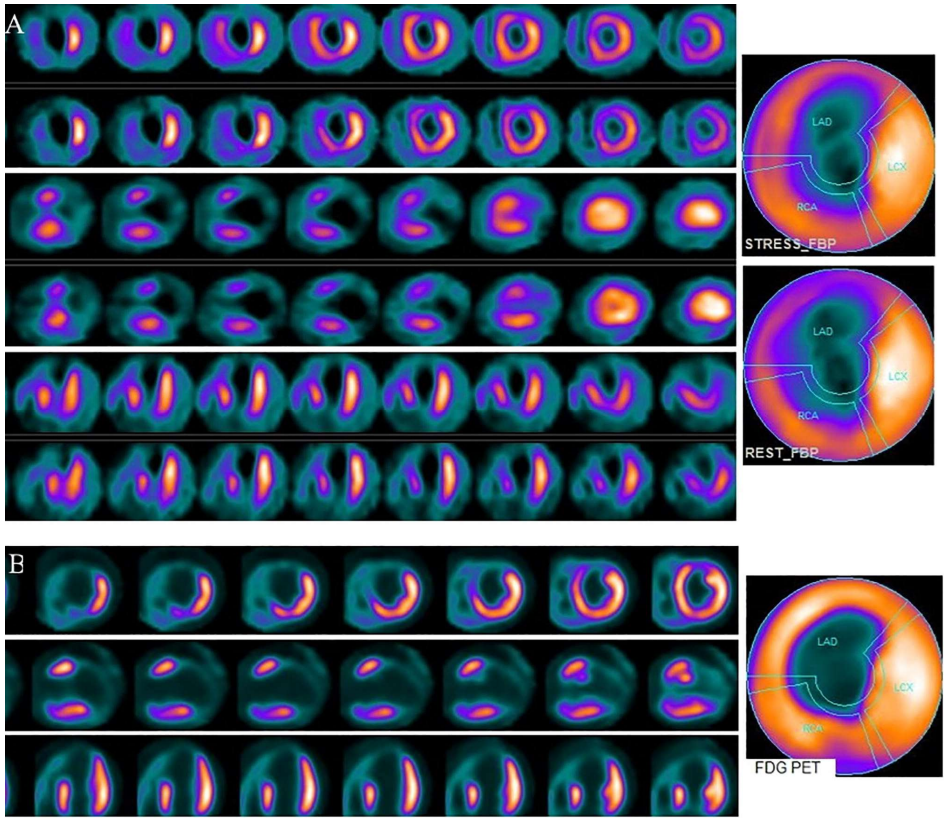

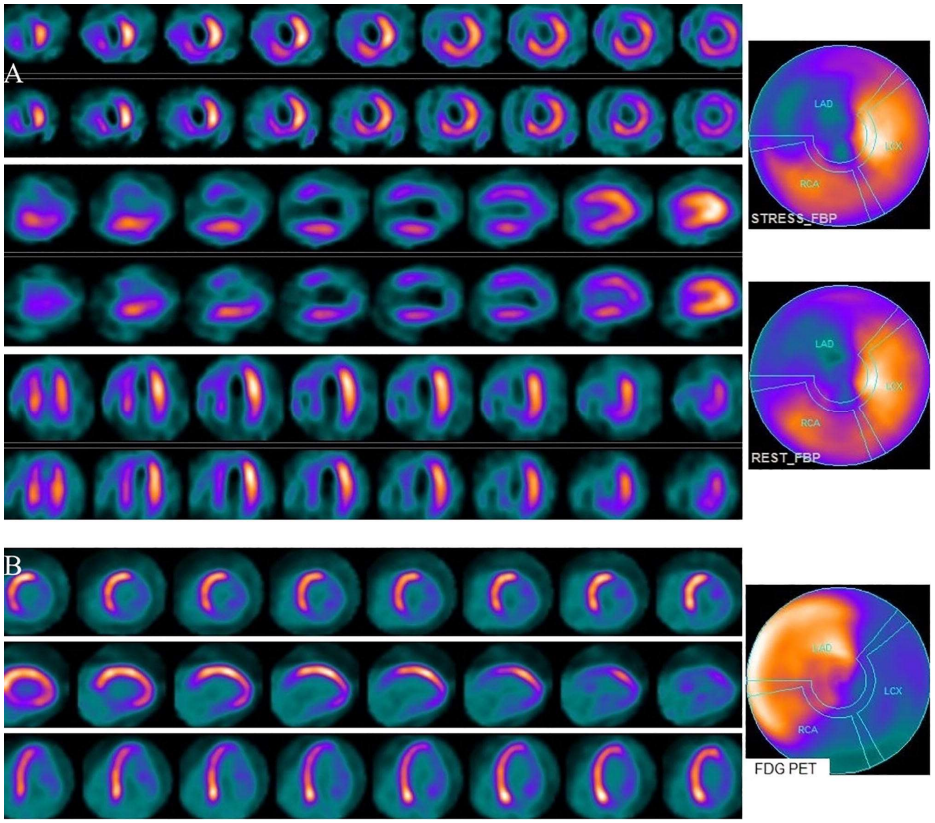

MARIA MIDDELARES

Sarikaya, I, 2018

Cardiale amyloïdose

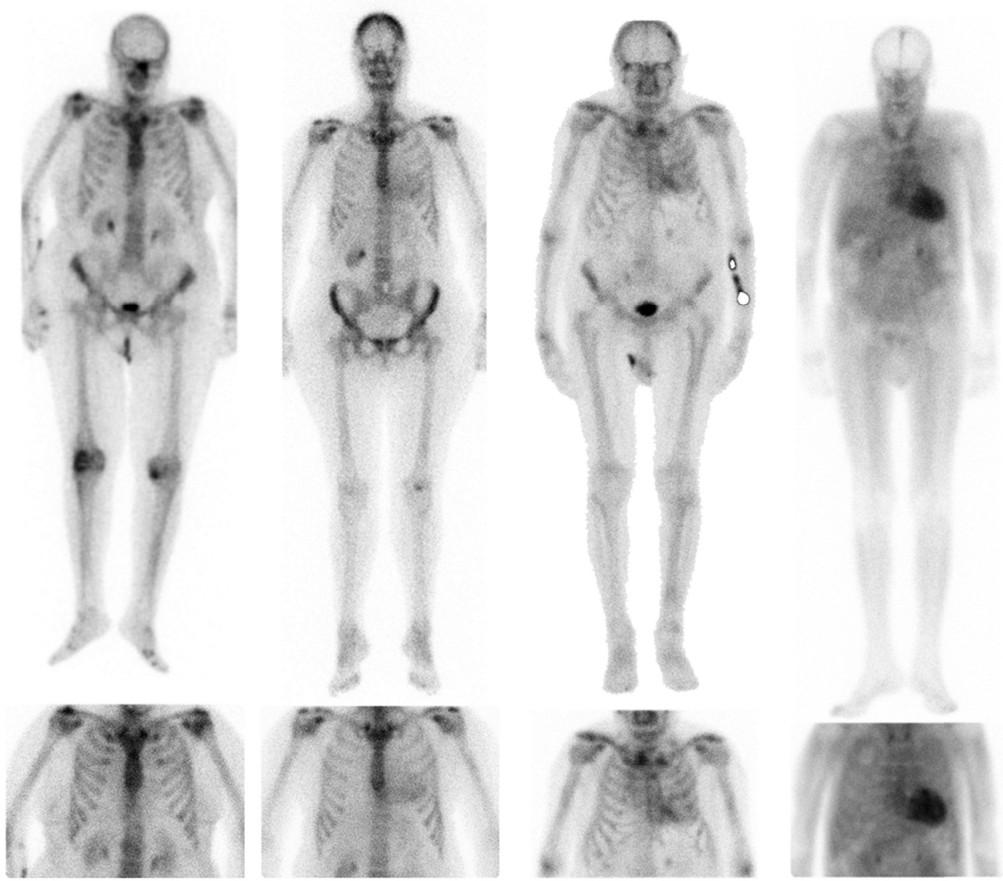

Diagnose van:
- Type ATTR-type cardiale amyloïdose

MARIA MIDDELARES

Wechalekar, A, JNC 2016
Lairez O, MN 2016

Functionele beeldvorming in nucleaire geneeskunde

- Informatie over processen, vaak met dynamische acquisitie
- Hybride beeldvorming, hogere specificiteit – nauwe samenwerking dienst radiologie
- Quantificatie mogelijk, vaak ook nuttig in de opvolging
- PET-applicaties

MARIA MIDDELARES

Dienst Nucleaire Geneeskunde

09 246 96 00

MARIA MIDDELARES

GezondheidsZorg met een Ziel