

Anterieure spiersparende heupprothese

Dr. Frederik Matthys
Heup- en bekkenchirurgie
Anterieure heupprothese
Young adult hip

MARIA MIDDELARES
GezondheidsZorg met een Ziel

Indicatie

80% primaire artrose

11.5% fracturen

4.5% avasculaire necrose

3% secundaire artrose

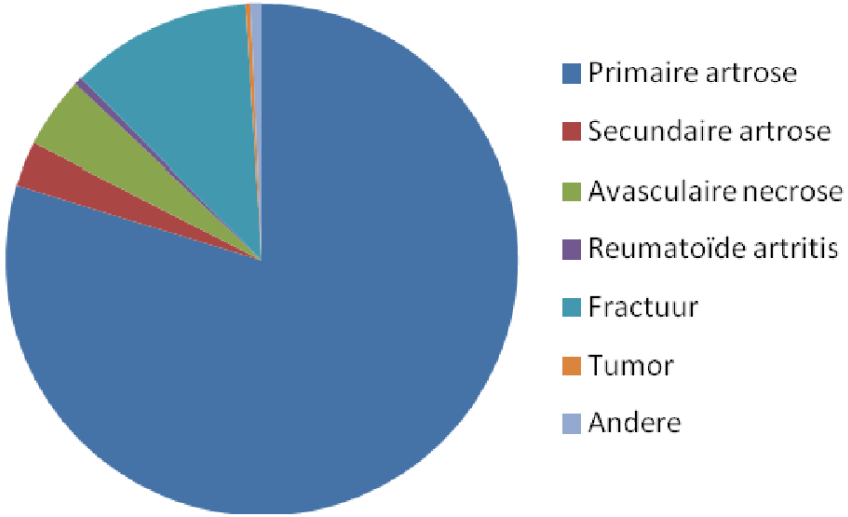

Figuur 2. Diagnose voor primaire procedures ter hoogte van de heup.

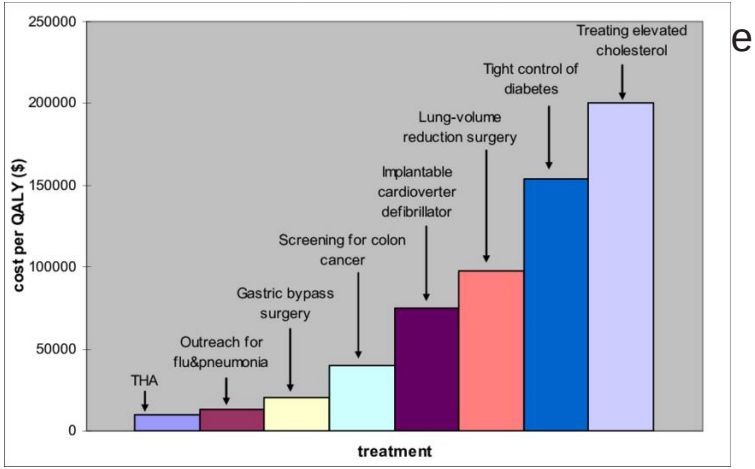

Heupprothese: meest kost-effectieve procedures van alle behandelingen in de geneeskunde.

MARIA MIDDELARES

Epidemiologie

In 2017 29.464 heupprothesen in België

Aantal neemt toe

- vergrijzing
- meer en meer jongere patiënten

Hogere verwachtingen

MARIA MIDDELARES

Overleving prothese

ARTICLES | VOLUME 393, ISSUE 10172, P647-654, FEBRUARY 16, 2019

How long does a hip replacement last? A systematic review and meta-analysis of case series and national registry reports with more than 15 years of follow-up

Jonathan T Evans, MRCS • Jonathan P Evans, MSc • Robert W Walker, MRCS • Prof Ashley W Blom, PhD • Michael R Whitehouse, PhD † • Adrian Sayers, MSc † • Show footnotes

Conclusion: Assuming that estimates from national registries are less likely to be biased, patients and surgeons can expect a hip replacement to last 25 years in around 58% of patients.

MARIA MIDDELARES

Toegangswegen

Fig. 3. Surgical approaches to the hip. Dotted line shows incisions on the right hip.

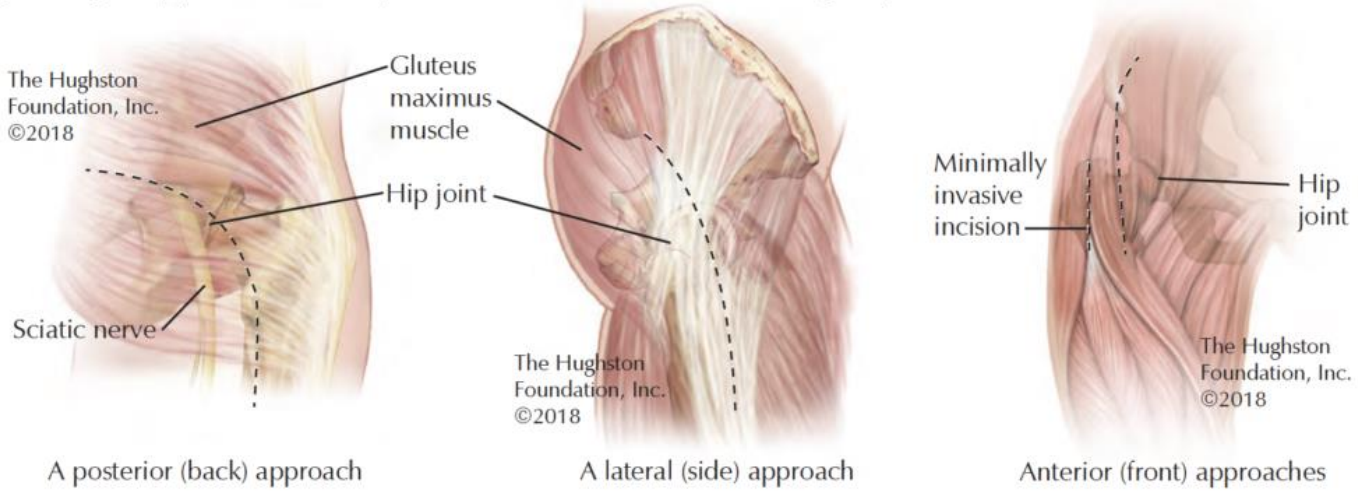

Posterieur

Wereldwijd veel gebruikt, goede zichtbaarheid MAAR: losmaken exorotatoren, n. ischiadicus, luxatierisico

Anterolateraal

Losmaken deel van gluteus spier, Trendelenburg/manken

Direct anterieur

Spiersparend

MARIA MIDDELARES

Toegangswegen

Orthopride

2013: 21-24% Anterieur

heden: **50%**

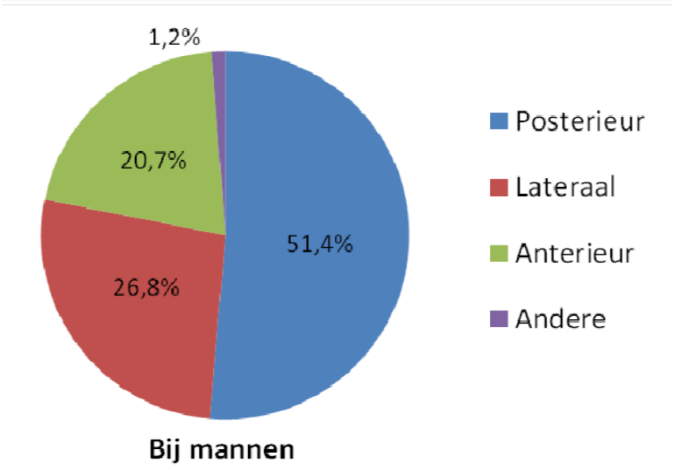

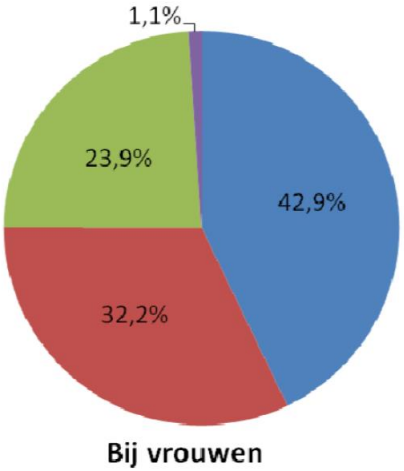

MARIA MIDDELARES

Procedure

incisie van het peesblad

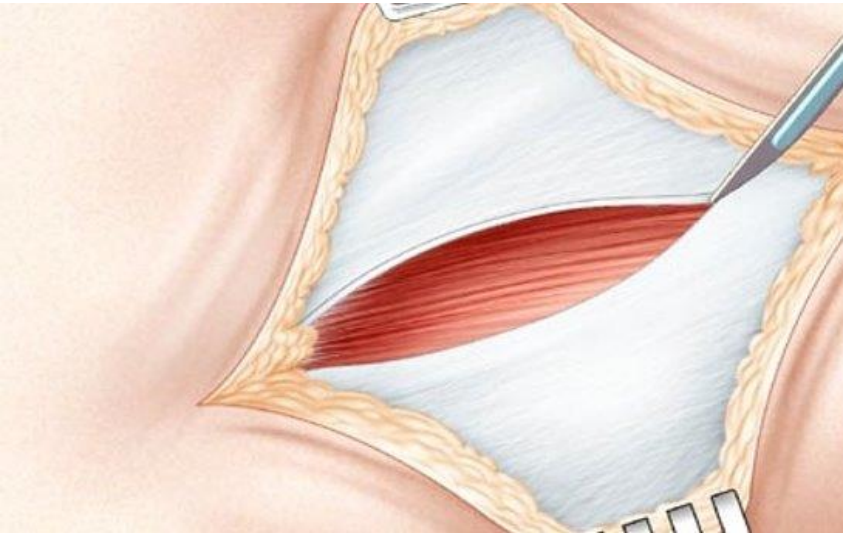

tussen de tensor en de rectus naar het heupgewricht

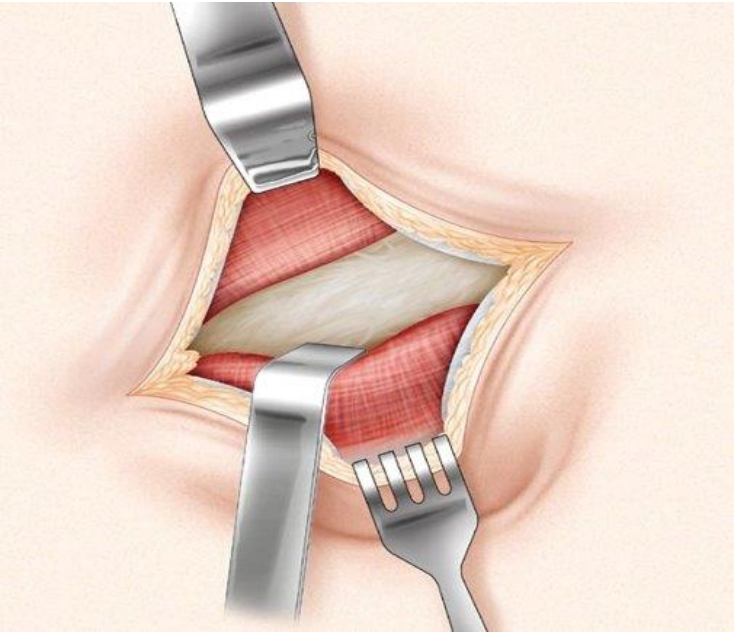

MARIA MIDDELARES

Procedure

openen van het gewrichtskapsel

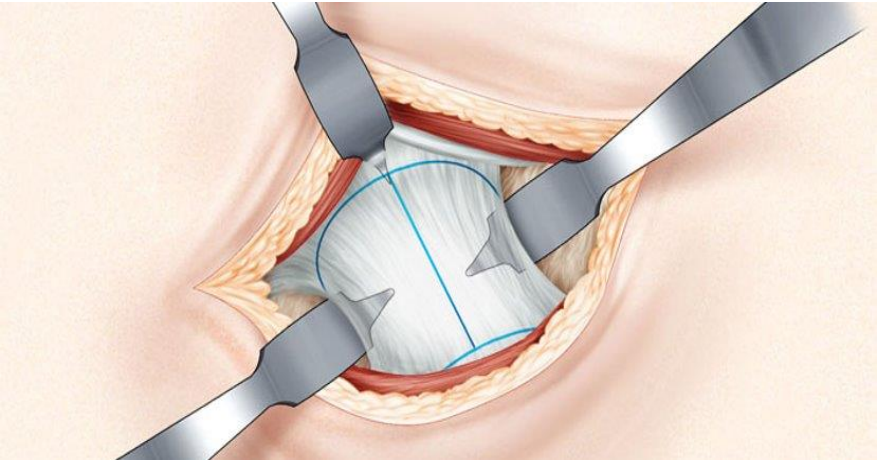

na osteotomie verwijderen van de heupkop

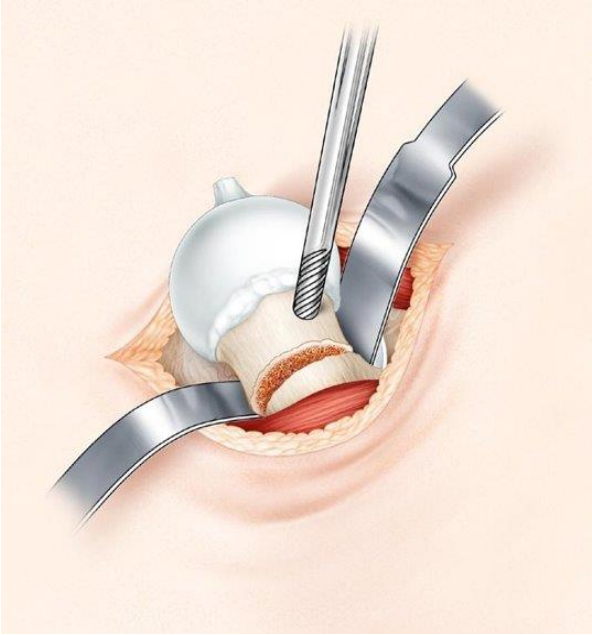

MARIA MIDDELARES

Procedure

acetabulum (pan) goed te visualiseren

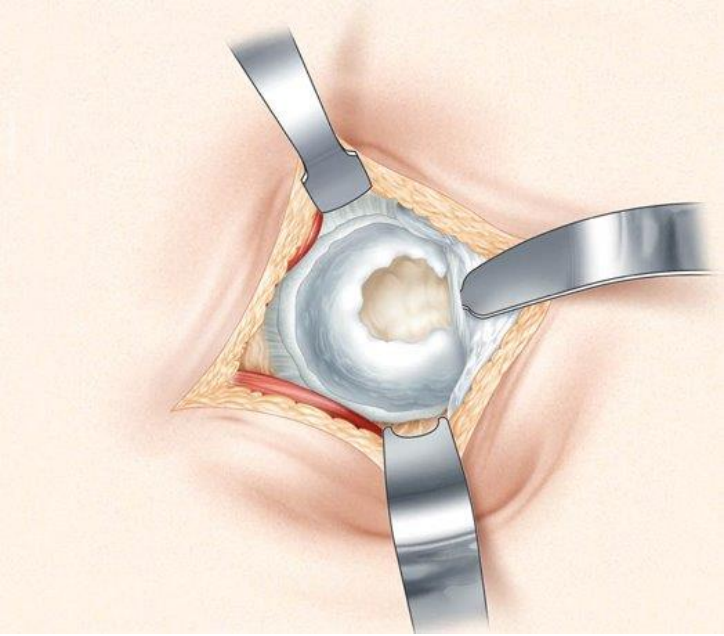

uitfrezen van de kom

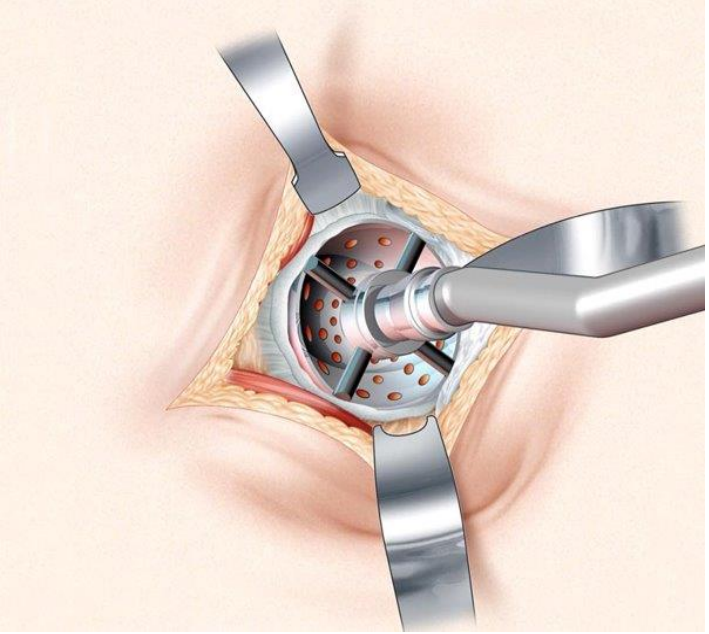

MARIA MIDDELARES

Procedure

plaatsen van de definitieve cup (pan)

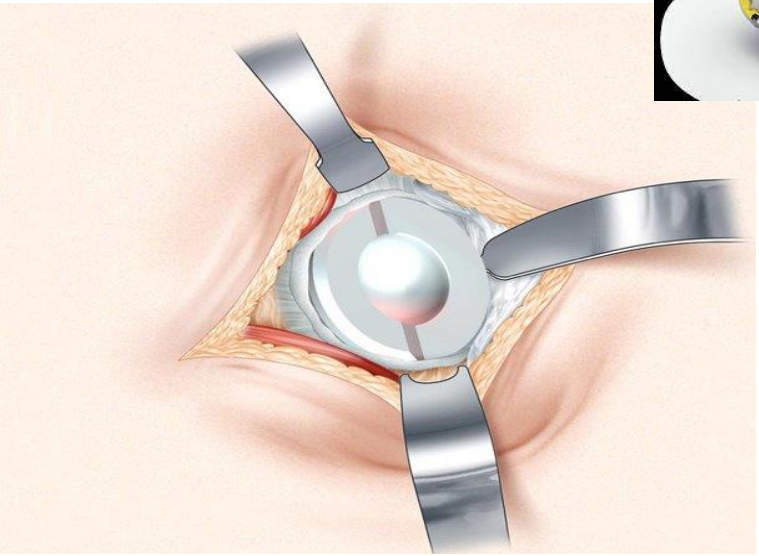

voorbereiden femurkanaal

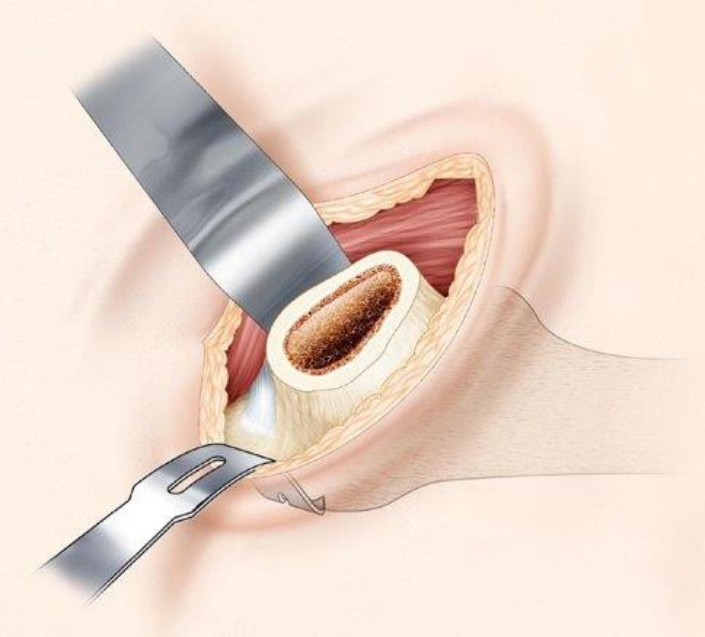

MARIA MIDDELARES

Procedure

progressief raspen van de femur

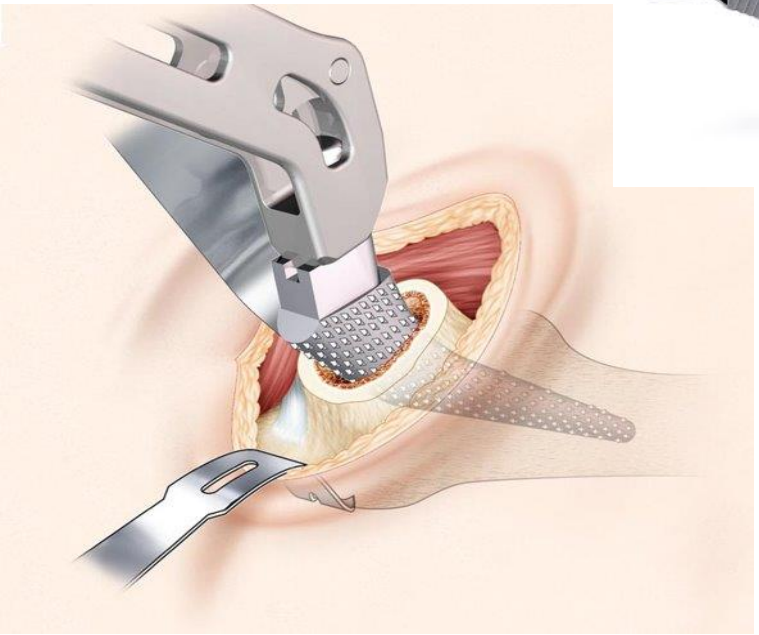

plaatsen van de definitieve prothese en reductie van het nieuwe heupgewricht

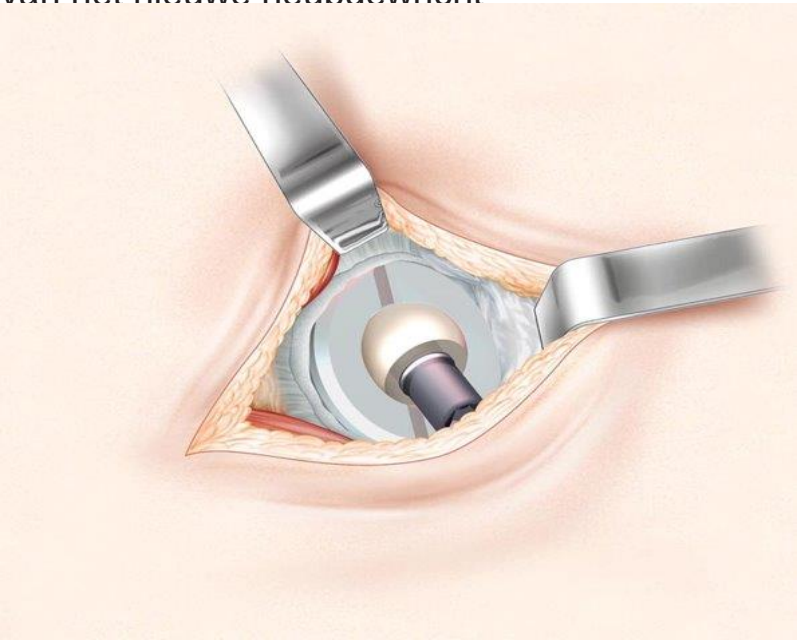

MARIA MIDDELARES

Casus

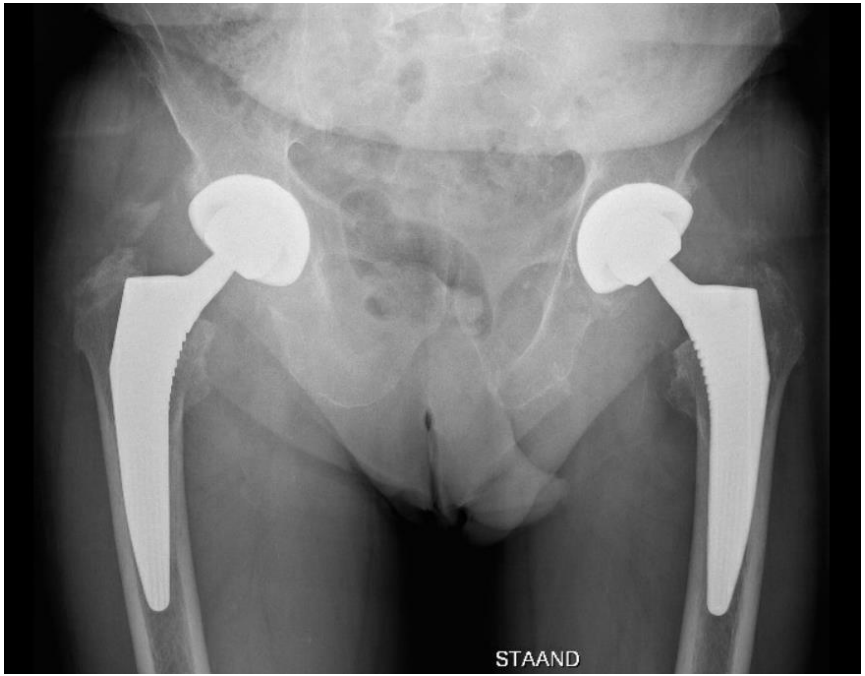

MARIA MIDDELARES

Bikini incisie

- cosmetisch
- richting van de huidlijnen
- minder wondproblemen/
  bloedverlies

MARIA MIDDELARES

Risico’s

- Mogelijke zenuwschade n. femoralis cutaneus lateralis (huidzenuw) veroorzaakt doof gevoel bovenbeen.
- Lange leercurve
- Zichtbaarheid is soms beperkt (gespierde jonge mannen)

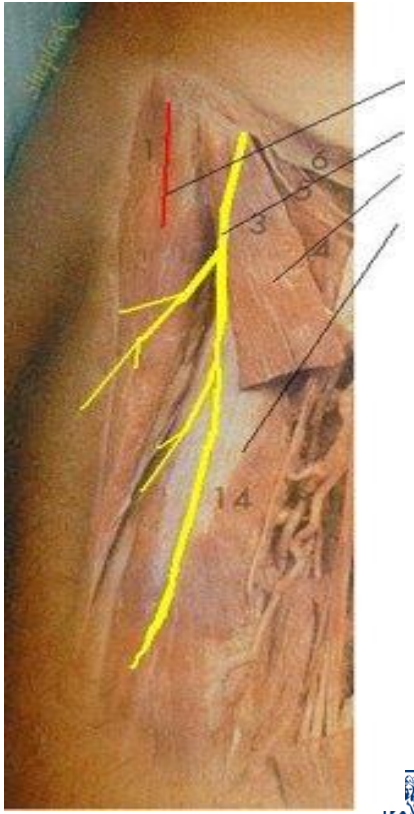

MARIA MIDDELARES

Revalidatie

Hip Int. 2020 Nov;30(6):695-702. doi: 10.1177/1120700019881413. Epub 2019 Oct 6.

Anterior versus posterior approach total hip arthroplasty: patient-reported and functional outcomes in the early postoperative period

Conclusions: Patients undergoing DA THA discontinued their assistive device, left their home, and drove a car sooner than posterior approach patients. We found improvement in physical function with DA, and it persisted up to 5 weeks postoperatively. Furthermore, DA patients had significantly shorter length of stay, improved mobilisation, decreased narcotic requirements and improved inpatient pain scores compared to posterior approach THA. Future randomised controlled study should be performed to minimise the biases inherent in this study methodology and confirm the results.

MARIA MIDDELARES

Mijn postoperatief beleid:

- 1 overnachting
- Geen wondzorg nodig
- Krukken voor een 2-tal weken
- Geen bewegingsbeperkingen
- Autorijden na een maand
- Zo gunstige follow up na 6 weken = geen enkele beperkingen meer qua activiteiten (bvb sporthervatting)

MARIA MIDDELARES

Besluit

Waarom anterieur spiersparend?

- Snellere revalidatie
- Minder complicaties (luxaties/wondproblemen)
- Betere controle over beenlengte

MARIA MIDDELARES



MARIA MIDDELARES

GezondheidsZorg met een Ziel